



doi:10.7659/j.issn.1005-6947.2022.03.003  
http://dx.doi.org/10.7659/j.issn.1005-6947.2022.03.003  
Chinese Journal of General Surgery, 2022, 31(3):304-309.

· 专题研究 ·

## 中段胰腺切除术19例临床分析

杨正江, 付晓伟, 孙根, 辛万鹏, 易思清, 姜海, 李勇, 肖卫东

(南昌大学第一附属医院 普通外科, 江西南昌 330006)

### 摘要

**背景与目的:** 胰十二指肠切除术 (PD) 和胰体尾切除术 (DP) 被认为是治疗胰腺肿瘤的标准术式。然而, 它们应用于治疗良性或低度恶性肿瘤时可能导致的胰腺内外分泌功能不足需引起重视。本研究旨在探讨中段胰腺切除术 (CP) 治疗胰颈部或近端体部良性或低度恶性肿瘤的临床疗效。

**方法:** 回顾性分析南昌大学第一附属医院 2009 年 6 月—2020 年 8 月间 19 例施行 CP 术患者的临床资料, 其中胰腺实性假乳头状瘤 8 例, 浆液性囊腺瘤 4 例, 神经内分泌肿瘤 4 例, 假性囊肿、副神经节瘤、炎性肉芽肿各 1 例。

**结果:** 15 例行开腹手术, 4 例行微创手术; 远端胰腺消化道重建方式包括胰管空肠黏膜吻合 15 例, 胰胃吻合 4 例。平均手术时间为  $(224.0 \pm 40.4)$  min, 平均术中出血量  $(173.2 \pm 50.9)$  mL。总体并发症和临床相关胰瘘发生率分别为 52.6% 和 26.3%。平均术后住院时间  $(11.8 \pm 6.5)$  d。无再次手术及手术相关死亡。平均随访时间  $(59.3 \pm 39.0)$  个月, 无 1 例发生胰腺内外分泌功能不足, 无肿瘤复发。

**结论:** CP 术治疗胰颈部或近端体部良性或低度恶性肿瘤能最大限度保留胰腺内外分泌功能, 但伴随相对较高的胰瘘发生率。

### 关键词

胰腺切除术; 胰腺肿瘤; 胰腺瘘  
中图分类号: R657.5

## Clinical analysis of central pancreatectomy in 19 cases

YANG Zhengjiang, FU Xiaowei, SUN Gen, XIN Wanpeng, YI Siqing, JIANG Hai, LI Yong, XIAO Weidong

(Department of General Surgery, the First Affiliated Hospital of Nanchang University, Nanchang 330006, China)

### Abstract

**Background and Aims:** Pancreaticoduodenectomy (PD) and distal pancreatectomy (DP) are considered as the standard procedures for pancreatic tumors. However, it needs to be noted that the endocrine and exocrine pancreatic insufficiency may occur after performing these two procedures for benign or low-grade malignant tumors. The aim of this study was to investigate the clinical efficacy of central pancreatectomy (CP) for benign or low-grade malignant tumors in the neck and proximal body of the pancreas.

**Methods:** The clinical data of 19 patients who underwent CP from June 2009 to August 2020 in the First Affiliated Hospital of Nanchang University were retrospectively analyzed. Among the patients, there

**基金项目:** 国家自然科学基金资助项目 (81860418); 江西省重点研发计划资助项目 (20192BBG70035); 江西省自然科学基金资助项目 (20202ACB206007); 南昌大学研究生创新专项资金资助项目 (CX2019160)。

**收稿日期:** 2021-03-28; **修订日期:** 2021-10-09。

**作者简介:** 杨正江, 南昌大学第一附属医院硕士研究生, 主要从事肝胆胰外科基础与临床方面的研究。

**通信作者:** 肖卫东, Email: frankxwd@126.com

were solid pseudopapillary tumor in 8 cases, serous cystadenoma in 4 cases, neuroendocrine tumor in 4 cases, and pseudocyst, paraganglioma and inflammatory granuloma in one case each.

**Results:** Fifteen patients underwent open surgery and 4 patients had minimally invasive surgery. The reconstruction methods of the distal pancreatic remnant included duct-to-mucosa pancreaticojejunostomy in 15 cases and pancreaticogastrostomy in 4 cases. The mean operative time was (224.0±40.4) min, and the mean intraoperative blood loss was (173.2±50.9) mL. The incidence rates of overall complications and clinically relevant postoperative pancreatic fistula were 52.6% and 26.3%, respectively. The mean postoperative hospital stay was (11.8±6.5) d. No reoperation and surgery-related death occurred. The mean follow-up time was (59.3±39.0) months, and endocrine or exocrine pancreatic insufficiency occurred in none of them as well as no tumor recurrence was noted.

**Conclusion:** CP for the treatment of benign or low-grade malignant lesions in the neck or proximal body of the pancreas can maximally preserve the endocrine and exocrine pancreatic function, but it is associated with a relative high incidence of pancreatic fistula.

**Key words** Pancreatectomy; Pancreatic Neoplasms; Pancreatic Fistula

**CLC number:** R657.5

中段胰腺切除术 (central pancreatectomy, CP) 主要用于治疗位于胰腺颈部或近端体部且不适合行单纯剜除术 (enucleation, EN) 的良性或低度恶性肿瘤。与传统的胰十二指肠切除术 (pancreaticoduodenectomy, PD) 和胰体尾切除术 (distal pancreatectomy, DP) 相比, CP术能够最大限度保留正常胰腺组织和其他毗邻脏器, 从而降低术后发生胰腺内外分泌功能不足的风险, 改善患者术后生活质量<sup>[1-3]</sup>。南昌大学第一附属医院普通外科2009年6月—2020年8月间共施行19例CP术, 现报告如下。

## 1 资料与方法

### 1.1 一般资料

男5例, 女14例; 年龄10~64岁, 平均(42.1±14.8)岁。有临床症状者11例, 其中腹痛、腹胀9例, 低血糖症状2例; 8例为体检发现胰腺占位; 2例合并2型糖尿病; 血清肿瘤标志物CEA、CA19-9、CA125均正常。所有患者术前B超、CT或MRI检查提示胰颈部或近端体部肿瘤, 考虑胰腺实性假乳头状瘤 (solid pseudopapillary tumor, SPT) 8例, 胰岛素瘤2例, 神经内分泌肿瘤 (neuroendocrine tumor, NET) 3例, 浆液性囊腺瘤 (serous cystadenoma, SCN) 4例, 黏液性囊腺瘤 (mucinous cystadenoma, MCN) 1例, 良性肿瘤病变1例。肿瘤最大直径2.2~13 cm, 平均(5.8±2.7) cm。

术后病理诊断: 胰腺SPT 8例, SCN 4例, NET 4例 (无功能性2例, 胰岛素瘤2例), 假性囊肿、副神经节瘤、炎性肉芽肿各1例。

### 1.2 手术情况

术式包括开腹中段胰腺切除术 (open central pancreatectomy, OCP) 与微创中段胰腺切除术 (minimally invasive central pancreatectomy, MICP), 后者包括腹腔镜手术 (laparoscopic central pancreatectomy, LCP) 与机器人辅助手术 (robot-assisted central pancreatectomy, RCP) (图1)。远端胰腺消化道重建方式: 胰管空肠黏膜吻合 (pancreaticojejunostomy, PJ) 或胰胃吻合 (pancreaticogastrostomy, PG)。所有患者均为单吻合, 近端胰腺 Endo-GIA (60 mm, 蓝钉, 强生公司) 切断后以4-0倒刺线或4-0 Prolene线连续缝合加固1道。

### 1.3 围手术期观察指标

观察指标包括手术时间、术中出血量、术后并发症以及术后住院时间。胰瘘、出血、胃排空延迟等并发症采用国际胰腺外科研究组和中华医学会外科学分会胰腺外科学组最新制订的诊断标准<sup>[4-7]</sup>, 并按Clavien-Dindo分级系统进行并发症分级<sup>[8-9]</sup>。B/C级胰瘘定义为临床相关胰瘘 (clinically relevant postoperative pancreatic fistula, CR-POPF)。

### 1.4 随访

通过电话或门诊随访, 截至2020年11月。随访内容包括临床症状、血糖水平以及影像学检查

(B超、CT或MRI)等。术后新发糖尿病或原有糖尿病加重(术后空腹或餐后2h血糖水平较术前水平升高,同时原有治疗药物剂量增加)诊断为胰腺内分泌功能不足。患者出现脂肪泻、体质量下

降症状,同时胰酶替代治疗后症状改善,和/或胰腺外分泌功能检查异常(72h粪便脂肪含量、 $^{13}C$ -混合甘油三酯呼气试验或粪便弹性蛋白酶1检测等)诊断为胰腺外分泌功能不足<sup>[10-11]</sup>。

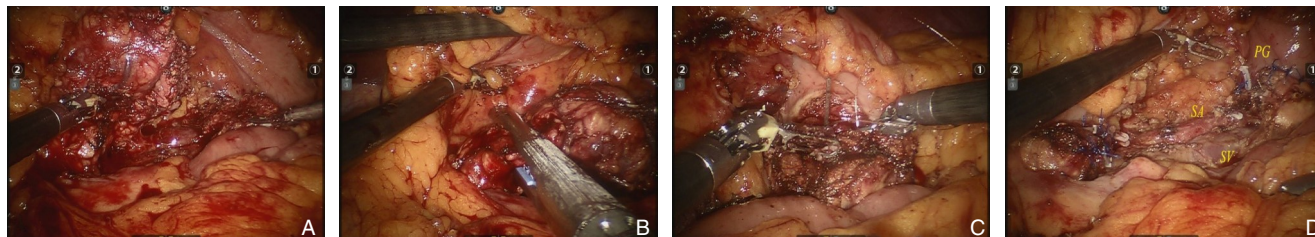


图1 RCP A: 切断胰腺远端; B: 切断胰腺近端; C: 胰胃吻合; D: 吻合完成

Figure 1 RCP A: Distal pancreas transection; B: Proximal pancreas transection; C: Pancreaticogastrostomy; D: Completion of anastomosis

## 2 结果

### 2.1 手术与术后情况

19例施行CP术患者的一般资料见表1。15例行OCP, 4例行微创手术(3例LCP, 1例RCP)。15例OCP中PJ 14例, PG 1例; 4例微创手术中辅助小切口PJ 1例, PG 3例。手术时间180~330 min, 平均 $(224.0 \pm 40.4)$  min, 术中出血量100~300 mL, 平均 $(173.2 \pm 50.9)$  mL。9例术后发生并发症, 其

中4例生化漏, 4例B级胰瘘, 1例B级胰瘘并腹腔内出血。按Clavien-Dindo并发症分级: I级4例, II级4例, IIIa级1例。总体并发症和CR-POPF发生率分别为47.4% (9/19)和26.3% (5/19)。合并生化漏者保持引流通畅, 无需其他特殊处理; B级胰瘘者给予腹腔持续冲洗引流、抑制胰酶分泌和抗感染等治疗; 腹腔内出血者给予止血、输血等治疗。无再次手术及手术相关死亡。术后住院时间8~33 d, 平均 $(11.8 \pm 6.5)$  d。

表1 患者的临床资料

Table 1 Clinical data of the patients

序号	年龄(岁)	性别	病理诊断	肿瘤最大径(cm)	手术方式	重建方式	并发症	术后住院时间(d)
1	58	女	胰岛素瘤	2.5	OCP	PJ	无	9
2	36	女	SPT	6	OCP	PJ	无	9
3	18	女	SPT	13	OCP	PJ	无	8
4	64	女	无功能性胰腺NET(G1)	3	OCP	PJ	生化漏	13
5	43	男	SPT	5	OCP	PJ	无	7
6	53	女	SPT	5	OCP	PJ	无	9
7	26	女	SPT	5.5	OCP	PJ	B级胰瘘、腹腔内出血	33
8	62	男	SCN	4	OCP	PJ	生化漏	11
9	42	女	副神经节瘤	5	OCP	PJ	生化漏	10
10	10	男	SPT	2.5	OCP	PJ	B级胰瘘	14
11	60	女	SCN	3.5	OCP	PJ	无	9
12	35	女	SPT	3.2	LCP	PJ	无	7
13	41	女	SCN	5	LCP	PG	无	9
14	30	男	肉芽肿性炎	2	LCP	PG	B级胰瘘	11
15	50	女	假性囊肿	4	OCP	PJ	生化漏	11
16	40	女	无功能性胰腺NET(G1)	4	OCP	PJ	B级胰瘘	17
17	32	女	SPT	6.5	OCP	PJ	无	7
18	47	女	胰岛素瘤	1.3	OCP	PG	B级胰瘘	23
19	52	男	SCN	2.5	RCP	PG	无	8

## 2.2 随访情况

所有患者均获随访,随访时间3~137个月,平均(59.3±39.0)个月。随访期内,无1例发生胰腺内外分泌功能不足,影像学检查提示无肿瘤复发。

## 3 讨论

近年来随着影像学及其他新技术的不断进步,越来越多的胰腺良性或低度恶性肿瘤被发现。EN、PD、DP、CP等多种术式均应用于胰颈部或近端体部良性或低度恶性肿瘤的治疗,尚无统一的选择标准。相对于传统的PD和DP术,各种保留器官的胰腺切除术是治疗胰腺良性或低度恶性肿瘤更合理的术式<sup>[12-15]</sup>,CP术是其中之一。

有关CP术的起源可以追溯至1908年,Ehrhardt用德文首次报道节段性胰腺切除术,两胰腺残端采用端端吻合。直到1982年,Dagradi和Serio为1例胰腺颈部胰岛素瘤患者实施了首例真正意义上的胰腺中段切除术,手术包括中段胰腺的切除和残端的重建<sup>[16]</sup>。到2014年有单中心完成100例CP术的报道<sup>[17]</sup>。CP术的主要适应证有:(1)直径2~5 cm的胰颈部或近端体部良性肿瘤或低度恶性肿瘤;(2)不宜单行EN的腺体深部的小肿瘤,因其损伤主胰管风险较高;(3)不宜行EN的非肿瘤性囊性病变更;(4)孤立性胰腺颈部转移瘤;(5)局灶性慢性胰腺炎伴主胰管狭窄;(6)外伤性胰腺颈部损伤等。而对于恶性肿瘤、合并胰体尾部萎缩等不建议行CP术<sup>[18]</sup>。本组患者经术前检查基本符合上述适应证,有1例患者肿瘤最大直径为13 cm,由于肿瘤呈外生型生长,因此选择施行了CP术。

CP术的最大优势在于最大限度保留正常胰腺组织,降低术后胰腺内外分泌功能不足的风险。文献<sup>[19]</sup>报道,良性肿瘤PD术后新发糖尿病发生率为14.5%,胰腺外分泌功能不足发生率为25.2%;DP术后胰腺内分泌功能不足发生率为12.6%~30.2%,外分泌功能不足发生率为20.2%<sup>[20-21]</sup>;CP术后胰腺内、外分泌功能不足的发生率则分别为4%和5%,显著低于PD和DP术<sup>[22]</sup>。李伟强等<sup>[23]</sup>报道胰腺良性和低度恶性肿瘤分别接受CP术(32例)、PD术(30例)和DP术(36例),结果显示:CP组术后新发糖尿病发生率显著低于PD组和DP组(3.1% vs. 16.7%; 3.1% vs. 25.0%, 均  $P <$

0.05),PD组和DP组需要胰酶替代发生率分别为26.7%和13.9%,而CP组为0( $P < 0.05$ )。本组19例患者,术后平均随访59.3个月,无1例发生胰腺内外分泌功能不足,也体现出CP术的远期优势。

CP术后胰痿发生率较高,究其原因主要有:术后残余2个胰腺断面;剩余胰腺组织较多致胰液分泌更多;患者多为良性肿瘤,其胰腺实质较软、胰管直径小,两者均为术后发生胰痿的高危因素。Paiella等<sup>[24]</sup>报道116例CP术,B/C级胰痿发生率为26.7%。Goudard等<sup>[17]</sup>报道100例CP术,B/C级胰痿发生率为44%。荟萃分析<sup>[22,25]</sup>显示,CP术后胰痿发生率显著高于PD术和DP术。本组临床相关胰痿发生率为26.3%,无C级胰痿,所有并发胰痿患者经保守治疗均痊愈。由此可见,尽管CP术后胰痿发生率较高,但导致严重后果者甚少,综合考虑其减少胰腺内外分泌功能不足风险的远期优势,笔者认为,CP术是治疗胰颈部或近端体部良性或低度恶性肿瘤的一种合理术式。

中段胰腺切除后残胰消化道重建方式主要有两种:一是单吻合,即胰腺近端闭合,远端胰腺行PJ或PG;二是双吻合,即胰腺近、远端分别与空肠行“Ω”式吻合。笔者进行的一项系统评价<sup>[22]</sup>发现,在开腹组,PJ和PG分别占52%、44%;而在微创组,PJ和PG分别占46%、54%;Ω吻合则很少应用。PJ和PG术后胰痿发生率分别为33.0%和37.8%,两者差异无统计学意义。对于CP术后主胰管缺损≤5 cm者,也有选择主胰管架桥修复加端端吻合的报道<sup>[26]</sup>。本组19例中,PJ 15例,PG 4例。笔者体会,在微创手术时,PG合操作相对简便,同时可减少吻合口,节省手术时间。

近年来随着微创技术和设备的发展,MICP已在临床逐步开展。2003年,Baca等<sup>[27]</sup>报道了首例LCP,Giulianotti等<sup>[28]</sup>首次开展RCP,与传统开腹手术相比,MICP具有创伤小、出血少,恢复快等优点。Zhang等<sup>[29]</sup>对比分析了17例LCP与19例OCP的临床疗效,结果显示,两组的手术时间、术后住院时间、并发症发生率和B级以上胰痿发生率差异均无统计学意义;LCP组术中失血量明显低于OCP组,术后肠道功能恢复时间及禁食时间更短,远期生活质量更好。Shi等<sup>[30]</sup>报道110例RCP与60例OCP的临床疗效对比,结果显示,两组的总体并发症、出血、B/C级胰痿以及再手术发生率差异均无统计学意义;但RCP组手术时间短,术中

出血量少及切口感染少。本组共施行 4 例 MICP, 手术均顺利, 无术中输血, 1 例并发生化漏, 术后住院 7~11 d。由于本组 MICP 病例数少, 未与开腹手术做进一步比较。但可以预见, 腹腔镜和机器人手术将是今后 CP 术临床应用的发展方向。

利益冲突: 所有作者均声明不存在利益冲突。

## 参考文献

- [1] Iacono C, Verlato G, Ruzzenente A, et al. Systematic review of central pancreatectomy and meta-analysis of central versus distal pancreatectomy[J]. *Br J Surg*, 2013, 100(7):873-885. doi: 10.1002/bjs.9136.
- [2] Du ZY, Chen S, Han BS, et al. Middle segmental pancreatectomy: A safe and organ-preserving option for benign and low-grade malignant lesions[J]. *World J Gastroenterol*, 2013, 19(9): 1458-1465. doi: 10.3748/wjg.v19.i9.1458.
- [3] Xiang GM, Tan CL, Zhang H, et al. Central pancreatectomy for benign or borderline lesions of the pancreatic neck: a single centre experience and literature review[J]. *Hepatogastroenterology*, 2012, 59(116):1286-1289. doi: 10.5754/hge11937.
- [4] Wente MN, Veit JA, Bassi C, et al. Postpancreatectomy hemorrhage (PPH): an International Study Group of Pancreatic Surgery (ISGPS) definition[J]. *Surgery*, 2007, 142(1):20-25. doi: 10.1016/j.surg.2007.02.001.
- [5] Wente MN, Bassi C, Dervenis C, et al. Delayed gastric emptying (DGE) after pancreatic surgery: a suggested definition by the International Study Group of Pancreatic Surgery (ISGPS) [J]. *Surgery*, 2007, 142(5):761-768. doi:10.1016/j.surg.2007.05.005.
- [6] Bassi C, Marchegiani G, Dervenis C, et al. The 2016 update of the International Study Group (ISGPS) definition and grading of postoperative pancreatic fistula: 11 Years After[J]. *Surgery*, 2017, 161(3):584-591. doi: 10.1016/j.surg.2016.11.014.
- [7] 中华医学会外科学分会胰腺外科学组, 中国研究型医院学会胰腺病专业委员会, 中华外科杂志编辑部. 胰腺术后外科常见并发症诊治及预防的专家共识(2017)[J]. *中华外科杂志*, 2017, 55(5): 328-334. doi: 10.3760/cma.j.issn.0529-5815.2017.05.003.  
Study Group of Pancreatic Surgery in Chinese Society of Surgery of Chinese Medical Association, Pancreatic Disease Committee of Chinese Research Hospital Association, Editorial Board of Chinese Journal of Surgery. A consensus statement on the diagnosis, treatment, and prevention of common complications after pancreatic surgery (2017)[J]. *Chinese Journal of Surgery*, 2017, 55(5):328-334. doi: 10.3760/cma.j.issn.0529-5815.2017.05.003.
- [8] Dindo D, Demartines N, Clavien PA. Classification of surgical complications: a new proposal with evaluation in a cohort of 6336 patients and results of a survey[J]. *Ann Surg*, 2004, 240:205-213. doi: 10.1097/01.sla.0000133083.54934.ae.
- [9] Clavien PA, Barkun J, de Oliveira ML, et al. The Clavien-Dindo classification of surgical complications: five-year experience[J]. *Ann Surg*, 2009, 250(2):187-196. doi: 10.1097/SLA.0b013e3181b13ca2.
- [10] Roeyen G, Jansen M, Ruysinck L, et al. Pancreatic exocrine insufficiency after pancreaticoduodenectomy is more prevalent with pancreaticogastrostomy than with pancreaticojejunostomy. A retrospective multicentre observational cohort study[J]. *HPB (Oxford)*, 2016, 18(12): 1017-1022. doi: 10.1016/j.hpb.2016.09.002.
- [11] 中华医学会外科学分会胰腺外科学组, 中国研究型医院学会胰腺病专业委员会. 胰腺术后外分泌功能不全诊治的中国专家共识(2018)[J]. *中华外科杂志*, 2018, 56(9):641-645. doi: 10.3760/cma.j.issn.0529-5815.2018.09.001.  
Study Group of Pancreatic Surgery in Chinese Society of Surgery of Chinese Medical Association, Pancreatic Disease Committee of Chinese Research Hospital Association. A consensus statement on the diagnosis and treatment of pancreatic exocrine insufficiency after pancreatic surgery (2018) [J]. *Chinese Journal of Surgery*, 2018, 56(9): 641-645. doi: 10.3760/cma. j. issn. 0529-5815.2018.09.001.
- [12] Lee SE, Jang JY, Hwang DW, et al. Clinical efficacy of organ-preserving pancreatectomy for benign or low-grade malignant potential lesion[J]. *J Korean Med Sci*, 2010, 25(1): 97-103. doi: 10.3346/jkms.2010.25.1.97.
- [13] 肖卫东, 林生荣, 吴安涛, 等. 保留器官的胰腺切除术治疗胰腺良性或低度恶性肿瘤: 单中心 66 例报告[J]. *中国普通外科杂志*, 2018, 27(3):284-288. doi:10.3978/j.issn.1005-6947.2018.03.003.  
Xiao WD, Lin SR, Wu AT, et al. Organ preserving pancreatectomy for pancreatic benign or low-grade malignant tumor: a report of 66 cases in a single institution[J]. *Chinese Journal of General Surgery*, 2018, 27(3):284-288. doi:10.3978/j.issn.1005-6947.2018.03.003.
- [14] Beger HG. Benign Tumors of the Pancreas-Radical Surgery Versus Parenchyma-Sparing Local Resection-the Challenge Facing Surgeons[J]. *J Gastrointest Surg*, 2018, 22(3): 562-566. doi: 10.1007/s11605-017-3644-2.
- [15] Zhang RC, Ma J, Mou YP, et al. Short- and Long-Term Outcomes of Laparoscopic Organ-Sparing Resection for Pancreatic Neuroendocrine Neoplasms[J]. *World J Surg*, 2020, 44(11):3795-3800. doi: 10.1007/s00268-020-05707-8.
- [16] Iacono C, Ruzzenente A, Bortolasi L, et al. Central pancreatectomy: The Dagradi Serio Iacono operation. Evolution of a surgical technique from the pioneers to the robotic approach[J].

- World J Gastroenterol, 2014, 20(42): 15674–15681. doi: 10.3748/wjg.v20.i42.15674.
- [17] Goudard Y, Gaujoux S, Dokmak S, et al. Reappraisal of central pancreatectomy a 12-year single-center experience[J]. JAMA Surg, 2014, 149(4):356–363. doi: 10.1001/jamasurg.2013.4146.
- [18] 付晓伟, 肖卫东. 胰腺中段切除术在胰腺外科中的地位[J]. 中华肝脏外科手术学电子杂志, 2019, 8(3):192–195. doi:10.3877/cma.j.issn.2095-3232.2019.03.004.
- Fu XW, Xiao WD. The role of central pancreatectomy in pancreatic surgery[J]. Chinese Journal of Hepatic Surgery, 2019, 8(3): 192–195. doi:10.3877/cma.j.issn.2095-3232.2019.03.004.
- [19] Beger HG, Poch B, Mayer B, et al. New Onset of Diabetes and Pancreatic Exocrine Insufficiency After Pancreaticoduodenectomy for Benign and Malignant Tumors: A Systematic Review and Meta-analysis of Long-term Results[J]. Ann Surg, 2018, 267(2): 259–270. doi: 10.1097/SLA.0000000000002422.
- [20] Kusakabe J, Anderson B, Liu J, et al. Long-Term Endocrine and Exocrine Insufficiency After Pancreatectomy[J]. J Gastrointest Surg, 2019, 23(8):1604–1613. doi: 10.1007/s11605-018-04084-x.
- [21] Hallac A, Aleassa EM, Rogers M, et al. Exocrine pancreatic insufficiency in distal pancreatectomy: incidence and risk factors[J]. HPB (Oxford), 2020, 22(2): 275–281. doi: 10.1016/j.hpb.2019.06.017.
- [22] Xiao WD, Zhu JS, Peng L, et al. The role of central pancreatectomy in pancreatic surgery: a systematic review and meta-analysis[J]. HPB (Oxford), 2018, 20(10): 896–904. doi: 10.1016/j.hpb.2018.05.001.
- [23] 李伟强, 窦科峰, 段涛, 等. 胰腺中段切除术治疗良性和低度恶性胰腺颈体部肿瘤: 附32例报告[J]. 中国普通外科杂志, 2014, 23(3):278–282. doi: 10.7659/j.issn.1005-6947.2014.03.002.
- Li WQ, Dou KF, Duan T, et al. Middle pancreatectomy for benign and low-grade malignant tumors of the pancreatic neck and body: a report of 32 cases[J]. Chinese Journal of General Surgery, 2014, 23(3):278–282. doi: 10.7659/j.issn.1005-6947.2014.03.002.
- [24] Paiella S, De Pastena M, Faustini F, et al. Central pancreatectomy for benign or low-grade malignant pancreatic lesions-A single-center retrospective analysis of 116 cases[J]. Eur J Surg Oncol, 2019, 45(5):788–792. doi: 10.1016/j.ejso.2018.11.021.
- [25] Regmi P, Yang Q, Hu HJ, et al. Overall Postoperative Morbidity and Pancreatic Fistula Are Relatively Higher after Central Pancreatectomy than Distal Pancreatic Resection: A Systematic Review and Meta-Analysis[J]. Biomed Res Int, 2020, 2020: 7038907. doi: 10.1155/2020/7038907.
- [26] 刘荣, 赵国栋. 创新性桥梁合拢理论对改变胰腺良性病外科手术方法的推动[J]. 中国普通外科杂志, 2018, 27(3):263–268. doi: 10.3978/j.issn.1005-6947.2018.03.001.
- Liu R, Zhao GD. Promotion of innovative theory of bridge closure in changing traditional surgical approaches for benign pancreatic diseases[J]. Chinese Journal of General Surgery, 2018, 27(3):263–268. doi: 10.3978/j.issn.1005-6947.2018.03.001.
- [27] Baca I, Bokan I. Laparoscopic segmental pancreas resection and pancreatic cystadenoma[J]. Chirurg, 2003, 74(10): 961–965. doi: 10.1007/s00104-003-0690-y.
- [28] Giulianotti PC, Sbrana F, Bianco FM, et al. Robot-assisted laparoscopic pancreatic surgery: single-surgeon experience[J]. Surg Endosc, 2003, 138(7):777–784. doi:10.1007/s00464-009-0825-4.
- [29] Zhang RC, Zhang B, Mou YP, et al. Comparison of clinical outcomes and quality of life between laparoscopic and open central pancreatectomy with pancreaticojejunostomy[J]. Surg Endosc, 2017, 31(11):4756–4763. doi: 10.1007/s00464-017-5552-7.
- [30] Shi YH, Jin JB, Huo Z, et al. An 8-year single-center study: 170 cases of middle pancreatectomy, including 110 cases of robot-assisted middle pancreatectomy[J]. Surgery, 2020, 167(2):436–441. doi: 10.1016/j.surg.2019.09.002.

( 本文编辑 宋涛 )

本文引用格式: 杨正江, 付晓伟, 孙根, 等. 中段胰腺切除术19例临床分析[J]. 中国普通外科杂志, 2022, 31(3):304–309. doi: 10.7659/j.issn.1005-6947.2022.03.003

Cite this article as: Yang ZJ, Fu XW, Sun G, et al. Clinical analysis of central pancreatectomy in 19 cases[J]. Chin J Gen Surg, 2022, 31(3): 304–309. doi: 10.7659/j.issn.1005-6947.2022.03.003