



doi:10.7659/j.issn.1005-6947.2022.04.005  
http://dx.doi.org/10.7659/j.issn.1005-6947.2022.04.005  
Chinese Journal of General Surgery, 2022, 31(4):441-448.

· 专题研究 ·

## 术前渐进性气腹联合A型肉毒毒素在巨大切口疝修补术中的应用价值

汤福鑫<sup>1</sup>, 马宁<sup>2</sup>, 刘创雄<sup>2</sup>, 黄恩民<sup>2</sup>, 马涛<sup>2</sup>, 陈双<sup>2</sup>, 王辉<sup>1</sup>, 周太成<sup>2</sup>

(中山大学附属第六医院 1. 结直肠外科 2. 胃肠、疝和腹壁外科, 广东 广州 510655)

### 摘要

**背景与目的:** 巨大切口疝修复通常是一项具有挑战性的手术, 由于关闭巨大缺损可能会产生严重的病理生理后果, 甚至发生腹腔室隔综合征 (ACS) 等危及生命的并发症。术前渐进性气腹 (PPP) 可以扩大患者腹腔, 促进疝内容物重新回纳, 而A型肉毒毒素 (BTA) 可以可逆性松弛腹壁肌肉, 两者联合用于巨大切口疝修复术的术前准备可能起到互补作用。因此, 本研究探讨PPP联合BTA在巨大切口疝修补术中的应用价值。

**方法:** 回顾性分析2018年6月—2021年12月中山大学附属第六医院采用PPP联合BTA行腹腔镜下腹腔内补片植入术 (IPOM) 术前准备, 治疗的巨大切口疝患者7例临床资料。患者术先在超声引导下进行侧腹壁肌肉BTA注射以及腹腔置管建立PPP, 利用CT软件测量患者PPP+BTA处理前后侧腹壁肌肉长度、厚度以及疝囊容积 (VIH) 和腹腔容积 (VAC) 变化, 记录PPP+BTA处理后的不良反应, 术中、术后并发症及随访情况。

**结果:** 患者7例中, 男4例、女3例, 中位年龄59 (44~71) 岁, 中位体质指数25.6 (21.3~31.2) kg/m<sup>2</sup>; 6例患者为初发疝、1例患者为复发疝; 合并基础疾病2例。PPP+BTA处理后, 患者平均每边侧腹壁肌肉长度增加3.5 cm; 平均每边侧腹壁肌肉厚度减小0.3 cm; VIH平均增加量为829 mL、VAC平均增加量为2 982 mL、VIH/VAC比值降低1.7%; 患者的疝内容物均有不同程度自行回纳腹腔。在PPP+BTA准备过程中, 2例患者出现腹胀腹痛, 1例患者出现肩背部疼痛, 1例患者出现皮下气肿, 均自行缓解。患者均顺利完成IPOM治疗, 平均手术时间为 (186 ± 114) min, 术后住院时间为 (6.4 ± 1.1) d。术后患者VAS评分均低于3分, 无需使用镇痛药物。术后1例患者出现低位小肠梗阻, 予以对症处理后缓解, 未出现ACS等严重并发症。平均随访时间 (10.4 ± 8.8) 个月, 未出现慢性疼痛、复发及补片感染等并发症。

**结论:** PPP+BTA行术前准备能够明显增加巨大切口疝患者的腹腔容积、延长侧腹壁肌肉长度, 有利于巨大缺损关闭和减少术后严重并发症发生, 值得临床推广应用。

### 关键词

切口疝; 疝修补术; 腹腔镜; 气腹, 人工; 肉毒毒素类

中图分类号: R656.2

**基金项目:** 广东省科技计划基金资助项目 (2021A1515410004)。

**收稿日期:** 2022-03-03; **修订日期:** 2022-04-08。

**作者简介:** 汤福鑫, 中山大学附属第六医院在读博士研究生, 主要从事软组织修复及疝外科方面的研究。

**通信作者:** 周太成, Email: zhoutch3@mail.sysu.edu.cn; 王辉, Email: wang89@mail.sysu.edu.cn

## Application value of preoperative progressive pneumoperitoneum plus botulinum toxin A injection in large incisional hernia repair

TANG Fuxin<sup>1</sup>, MA Ning<sup>2</sup>, LIU Chuangxiong<sup>2</sup>, HUANG Enmin<sup>2</sup>, MA Tao<sup>2</sup>, CHEN Shuang<sup>2</sup>, WANG Hui<sup>1</sup>, ZHOU Taicheng<sup>2</sup>

(1. Department of Colorectal Surgery 2. Department of Gastroenterological Surgery and Hernia Center, the Sixth Affiliated Hospital of Sun Yat-sen University, Guangzhou 510655, China)

### Abstract

**background and Aims:** Large incisional hernia repair is always a matter of challenge, because the closure of large defects may likely lead to serious pathophysiological consequences or even life-threatening complications such as abdominal compartment syndrome (ACS). The preoperative progressive pneumoperitoneum (PPP) can widen the abdominal cavity of the patients, and facilitate reduction of the hernia contents, and the botulinum toxin A (BTA) can cause revisable relaxation the abdominal wall muscles, so their combined use in preoperative preparation of large incisional hernia repair surgery is considered to produce a complementary effect. Therefore, this study was performed to evaluate the application value of PPP combined with BTA injections in large incisional hernia repair.

**Methods:** The clinical data of 7 patients with large incisional hernia undergoing laparoscopic intraperitoneal onlay mesh repair (IPOM) using the combination of PPP and BTA injections for preoperative preparation in the Sixth Affiliated Hospital of Sun Yat-sen University from June 2018 to December 2021 were retrospectively analyzed. Before operation, the patients underwent BTA injections into the lateral abdominal wall muscles and abdominal catheter insertion for the PPP under ultrasound guidance. The changes in the volumes of the incisional hernia (VIH), the volumes of abdominal cavity (VAC) and the length and thickness of the lateral abdominal wall muscle before and after PPP plus BTA treatment were measured by CT software. The adverse reactions after PPP plus BTA treatment, the intra- and postoperative complications and follow-up results were recorded.

**Results:** Among the 7 patients, 4 cases were males and 3 cases were females, with a median age of 59 (44–71) years and a median body mass index of 25.6 (21.3–31.2) kg/m<sup>2</sup>; 6 cases had primary hernia and one case had recurrent hernia; 2 cases complicated with underlying diseases. After PPP plus BTA treatment, the average increase in length of the lateral abdominal muscle on each side was 3.5 cm, the average decrease in thickness of the abdominal wall muscle on each side was 0.3 cm, the average increasing value of VIH was 829 mL, the average increasing value of VAC was 2 982 mL, and the average decreasing value of VIH/VAC ratio was 1.7%, respectively; varying degrees of spontaneous reduction of the hernia contents into the abdominal cavity occurred in all patients. During PPP plus BTA preparation, abdominal distention and abdominal pain occurred in 2 patients, shoulder and back pain occurred in one patient, and subcutaneous emphysema occurred in one patient, but all resolved spontaneously without special treatment. The IPOM operation was uneventfully completed in all patients, the average operative time was (186±114) min and the length of postoperative hospital stay was (6.4±1.1) d. The postoperative VAS scores for all patients were lower than 3, and no analgesic supplement was needed. After surgery, low intestinal obstruction occurred in one patient, which was relieved after symptomatic treatment, and no serious complications such as ACS occurred. The average follow-up time was (10.4±8.8) months, and no chronic pain, recurrence and mesh infection complications were observed.

**Conclusion:** PPP plus BTA treatment for preoperative preparation can significantly increase the

abdominal volume of large incisional hernia and prolong the length of the lateral abdominal muscles of the patients, which is helpful for defect closure and reducing the occurrence of serous postoperative complications. So, it is recommended to be use in clinical practice.

**Key words**

Incisional Hernia; Herniorrhaphy; Laparoscopes; Pneumoperitoneum, Artificial; Botulinum Toxins

CLC number: R656.2

切口疝是腹部手术后常见并发症, 近期一项来自法国的研究<sup>[1]</sup>表明剖腹手术后5年切口疝累积发生率约5%, 而在部分高风险患者中发生率高达17%。随着材料学、外科学的发展, 切口疝手术效果大大提高, 但切口疝的高复发率仍然是相当大的挑战。Rhemtulla等<sup>[2]</sup>一项16 169例患者大数据研究发现切口疝发生率为3.1%, 其中20%的患者需要行复发切口疝修补, 23%的患者需要行二次复发切口疝修补。同时, 有些疝逐渐发展为巨大切口疝等复杂腹壁疝, 使得修补更加困难。巨大切口疝患者肠管、网膜等长期疝出原有腹腔以及腹壁肌肉的慢性收缩使腹腔真正容积减少 (loss of domain hernias, LODH), 若直接回纳疝内容物, 术后易致呼吸、循环、脏器功能紊乱, 甚至发生腹腔室隔综合征 (abdominal compartment syndrome, ACS) 等严重并发症而危及生命<sup>[3]</sup>。因此, 针对巨大切口疝患者, 术前进行充分的准备至关重要。

阿根廷学者Moreno<sup>[4]</sup>提出术前行渐进性气腹治疗 (preoperative progressive pneumoperitoneum, PPP) 是解决上述复杂问题的方法。PPP因能在术前逐渐增加腹腔容积 (the volumes of the abdominal cavity, VAC), 促进疝内容物重新回纳腹腔, 改善心肺功能, 使巨大切口疝患者术后发生ACS的风险大大降低<sup>[5]</sup>。Cunha等<sup>[6]</sup>报道了16例复杂腹壁疝患者, 通过平均11 d的PPP准备后, VAC平均增加了4 070.99 mL, 疝囊容积 (the volumes of the incisional hernia, VIH) /VAC降低了3%, 明显有利于缺损的关闭, 同时锻炼了患者的肺功能。Mancini等<sup>[7]</sup>报道了162例用PPP行术前准备的巨大腹壁疝患者, 95.7%患者取得缺损完全关闭, 但总体并发症发生率高达51.8%。A型肉毒杆菌毒素 (botulinum toxin type A, BTA) 是一种神经毒素, 可以阻断神经肌

肉接头处的乙酰胆碱受体, 术前将其注射到腹肌中, 可延长迟缓性麻痹和肌肉, 从而有利于手术缺损闭合和修复<sup>[8]</sup>, 近年来已逐渐应用到腹壁缺损修复领域。Bueno-Lledó等<sup>[9]</sup>回顾性分析了100例LODH的腹壁疝患者, 发现联合PPP与BTA治疗, VIH/VAC比值降低了15%, 97%患者取得缺损完全关闭, 但是大部分患者仍然需要使用组织结构分离技术进行修复。

本研究回顾笔者单位收治的7例巨大切口疝患者治疗情况, 探讨行PPP+BTA术前准备在巨大切口疝中的临床应用价值。

## 1 资料与方法

### 1.1 一般资料

回顾性分析2018年6月—2021年12月在中山大学附属第六医院胃肠、疝和腹壁外科7例采用PPP联合BTA行IPOM术术前准备的巨大切口疝患者临床资料。男4例, 女3例; 中位年龄59 (44~71)岁; 中位体质指数 (BMI) 25.6 (21.3~31.2)。6例患者为初发疝、1例患者为复发疝。合并基础疾病: 高血压2例、糖尿病1例 (表1)。所有患者按照美国麻醉医师协会 (ASA) 分级标准为1~2级, 无明显手术禁忌证。

### 1.2 入组标准

纳入标准: (1) 复发疝且VIH/VAC比>15%或巨大缺损且VIH/VAC比>10%或术前腹部CT示腹腔粘连严重; (2) 患者能耐受腹腔镜手术; (3) 患者依从性好, 包括愿意并能接受PPP和BTA注射。排除标准: 肌萎缩侧索硬化症、多发性神经病、重症肌无力、兰伯特-伊顿综合征等患者<sup>[10]</sup>, 慢性阻塞性肺疾病、前列腺增生症、过敏体质者等慎用。

表1 7例巨大切口疝患者基本资料

Table 1 General data of the 7 patients with large incisional hernia

病例序号	性别	年龄(岁)	BMI(kg/m <sup>2</sup> )	基础疾病	原发病	复发疝	位置	疝病程(月)
1	女	56	30.5	无	结肠癌	是	正中	16
2	女	50	27.8	无	结肠溃疡穿孔	否	左下腹	4
3	男	71	31.2	有	肝癌	否	正中	7
4	男	69	25.6	无	胃穿孔	否	正中	3
5	女	44	21.3	无	腹腔脓肿	否	正中	6
6	男	59	24.1	无	不详	否	正中	24
7	男	62	25.2	有	胰头癌	否	正中	6

### 1.3 术前准备

**1.3.1 常规行术前检查** 完善血常规、生化检查、凝血功能、X线胸片、腹部CT+疝囊腹腔容积重建(利用CT阅片软件勾勒腹部和疝囊的轮廓,计算出其腹腔和疝囊容积)、心电图、心肺功能、血气分析等检查。

**1.3.2 PPP和BTA注射** 根据Smoot等<sup>[1]</sup>报道的方法进行BTA注射。将100或150 U BTA用90 mL 0.9%氯化钠溶液稀释成6等份。患者取侧卧位,选取左、右腹壁各3个注射位点,位于腋前线第九肋缘水平与髂前上棘等距离的3个点,因疝部位、缺损程度不一,可做细微调整(例如左侧腹壁疝,注射位置可以相应靠左侧移动)。每点在超声引导下找到侧腹壁3层肌肉,先注射腹横肌,然后拔针再依次注射腹内斜肌、腹外斜肌,分别注射稀释后的BTA 5 mL(图1)。注射完毕后,患者恢复平卧位,在超声监视下,将14 Fr深静脉导管作为PPP导管置入上腹部腹腔中,远离之前的切口部位。需要注意的是,在进行BTA注射前,需备好抗过敏药物,注射完后观察30 min,注意患者有无头晕、胸闷气促等不适,防止过敏反应,如无不适即可恢复正常活动。回病房后首次注入200 mL空气,然后患者行站立位X线检查,确定PPP导管位于腹腔中,而后每天注入400 mL空气,持续2周左右。当出现以下情况时,PPP暂时终止:(1)腹痛、腹胀、肩痛等主观症状无法忍受;(2)呼吸困难、低氧血症或CO<sub>2</sub>滞留;(3)严重皮下、纵膈气肿。

### 1.4 手术方法

手术均由同一组医师完成,气管插管全身麻醉,患者取平卧位。建立气腹和观察孔:通过提前留置的人工气腹管注入CO<sub>2</sub>气体,气腹压力控制在12~14 mmHg(1 mmHg=0.133 kPa),结合术前腹部CT的影像,在疝缺损对侧腹壁腋前线至腋中线

区域,选择没有粘连或者粘连少的位置做一12 mm切口,使用12 mm穿刺器逐层突破进入腹腔作为观察孔;经观察孔置入腹腔镜镜头,鸟瞰整个腹腔,确认没有腹腔脏器损伤,然后拔出人工气腹管并在腹腔镜视野下建立剩余腹腔镜操作孔。分离腹腔粘连:腹腔镜直视下采用钝性加锐性相结合的方式分离疝囊周围粘连,回纳疝内容物,此过程应严格避免损伤肠管,尤其是电刀或者超声刀的热损伤,如果肠管有破损或疑似破损应及时进行修补。缝合关闭疝环缺损:结合切口疝“立体缝合”的技术,使用鱼骨线缝合关闭疝环缺损,消灭疝囊空间,增加腹壁厚度,提升腹壁对张力的承受能力,最终实现肌肉或筋膜缺损均匀有效的彻底关闭<sup>[2]</sup>。补片固定:将防粘连补片(巴德Ventralight ST Mesh补片或美敦力PCO补片)置入腹腔,采用“对位对线”补片固定法对补片进行固定,补片的覆盖范围应至少超过疝环口边缘5 cm;腹腔镜下观察补片放置的平整度,必要时需加固缝合,最后检查有无活动性出血,然后水化补片并放置引流。

### 1.5 术后处理

术后予以心电监测,密切监测患者血氧饱和度。予以补液,营养支持等处理,术后坚持佩带腹带6个月以上。

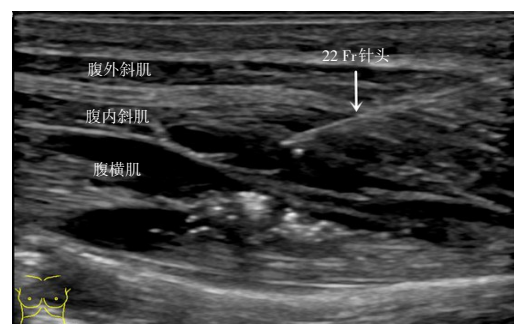


图1 超声引导下侧腹壁BTA注射

Figure 1 BTA injections of the lower lateral abdominal wall

### 1.6 术后随访

采用电话及门诊复查的方式。随访的内容包括:复发(外观可见腹壁局部凸起为疝囊,CT发现腹壁缺损)、血清肿、补片感染、疼痛等。

## 2 结果

### 2.1 PPP+BTA术前准备结果

患者7例平均PPP+BTA准备时间为(18.1±6.1)d, PPP+BTA处理后,患者每边侧腹壁肌肉长度均较

处理前增加,平均每边增加(3.5±1.5)cm;每边侧腹壁肌肉厚度均较处理前减小,平均每边厚度减小(0.3±0.1)cm。PPP+BTA处理后,VIH分别为(829±421)mL、(1074±603)mL;VAC分别为(6258±1412)mL、(9240±2155)mL;VIH/VAC比值分别为(13.6±6.1)%、(11.9±7.4)%,VIH平均增加量为829mL、VAC平均增加量为2982mL、VIH/VAC比值降低1.7%。7例患者PPP+BTA处理前后具体数据见表2-3。

表2 PPP+BTA前后疝大小、侧腹壁肌肉长度变化(cm)

Table 2 Changes in hernia size and length of the lateral abdominal wall muscle before and after PPP plus BTA treatment (cm)

病例序号	准备时间(d)	疝大小(横径×纵径)		左侧腹壁肌肉长度			右侧腹壁肌肉长度		
		PPP+BTA前	PPP+BTA后	PPP+BTA前	PPP+BTA后	差值	PPP+BTA前	PPP+BTA后	差值
1	10	10×20	12×21	10.7	15.6	4.9	17.7	19.8	2.1
2	20	9.0×16	14×17	9.5	13.4	3.9	9.8	14.7	4.9
3	21	8.0×12	9×12	13.4	19.8	6.4	15.1	19.4	4.3
4	20	11×18	13×20	16.0	20.1	4.1	14.7	18.6	3.9
5	23	9.0×17	8×17	10.5	12.5	2.0	11.3	12.7	1.4
6	9	15×9.0	15×7	16.9	18.6	1.7	17.1	18.1	1.0
7	24	15×10	15×11	15.5	20.2	4.7	14.2	18.4	4.2

表3 PPP+BTA前后VIH及VAC变化

Table 3 Changes in VIH and VAC before and after PPP plus BTA treatment

病例序号	PPP+BTA前			PPP+BTA后		
	VIH(mL)	VAC(mL)	VIH/VAC(%)	VIH(mL)	VAC(mL)	VIH/VAC(%)
1	704	5823	12.1	1347	8841	15.2
2	876	4000	21.9	1586	6672	23.8
3	1680	8121	20.7	1825	12678	14.4
4	817	5447	15.0	776	8876	8.7
5	378	5805	6.5	281	7685	3.6
6	859	7041	12.2	未知	未知	未知
7	490	7570	6.5	627	10687	5.9

行PPP+BTA后,疝内容物均有不同程度自行回纳腹腔(图2)。在准备过程中,2例患者出现腹

胀腹痛,1例患者出现肩背部疼痛,1例患者出现皮下气肿,但均自行缓解,未予特殊处理。

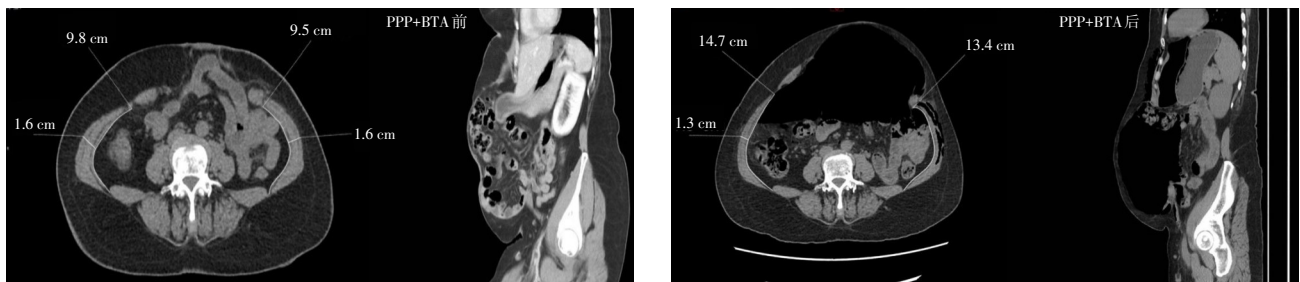

图2 PPP+BTA前后影像学变化

Figure 2 Changes in imaging findings before and after PPP plus BTA treatment

## 2.2 IPOM手术结果

患者均顺利接受腹腔镜IPOM手术治疗,平均手术时间为(186±114) min,术后住院时间为(6.4±1.1) d。术后患者VAS评分均低于3分,无需使用镇痛药物。术后1例患者出现低位小肠梗阻,予以对症处理后缓解,均未出现ACS等严重并发症。随访时间(10.4±8.8)个月,所有患者未出现慢性疼痛、复发及补片感染等并发症。

## 3 讨论

### 3.1 巨大切口疝治疗难点

首先,切口疝一旦发展成巨大切口疝,常常伴随LODH,成为“复杂疝”,处理非常棘手<sup>[13-14]</sup>,可导致术后腹腔内高压,并有发生急性肺衰竭和ACS的风险<sup>[15-18]</sup>。其次,巨大切口疝修补术中常需要联合组织结构分离技术<sup>[19-23]</sup>。常用的有开放或腹腔镜下的前入路组织结构分离<sup>[19-20]</sup>,后入路的腹横肌松解术<sup>[22, 24-25]</sup>,这些技巧能够增加腹腔容量,降低术后发生腹腔高压风险<sup>[26-27]</sup>。然而,研究表明组织结构分离技术带来高达30%的伤口并发症<sup>[15,21]</sup>,包括正常腹壁解剖结构的广泛破坏,术后伤口感染、皮肤坏死等并发症<sup>[19,28]</sup>。而以牺牲腹腔正常网膜、肠管等组织器官的主动减容技术易导致肠痿、补片感染等并发症。同时切除了正常的器官,使得患者部分生理功能丧失,得不偿失。

### 3.2 PPP与BTA作用机制、使用指征

PPP最早由Moreno教授<sup>[4]</sup>在1947年报道应用于巨大切口疝术前准备,随即在腹壁巨大疝修复领域获得广泛的应用<sup>[6-7,29]</sup>。PPP发挥作用的关键在于能够在术前逐渐增加VAC,同时改善肺部对腹腔高压的耐受能力,因而有助于术中缺损的关闭、疝内容物的完全回纳、减少术后ACS等并发症发生<sup>[30]</sup>。此外,PPP还能够松解腹腔粘连、帮助术者识别腹壁粘连区域、有助于术前Trocar定位<sup>[31]</sup>。关于单独PPP使用指征并没有明确定论,例如Tanaka等<sup>[32]</sup>推荐VIH/VAC>25%,Kingsnorth等<sup>[33]</sup>推荐VIH/VAC>15%~20%时则需要使用PPP进行术前准备。但由于单独使用PPP对侧腹壁肌肉无明显延长作用,因此巨大疝还需联合BTA以延长腹壁肌肉,更有利于巨大缺损的关闭<sup>[31]</sup>。本研究中,PPP后VAC平均增加量(2 982 mL)远大于VIH(1 074 mL),足

以容纳疝内容物的完全回纳。说明PPP在发挥松解粘连功效时,可以使得疝内容物自行部分回纳腹腔。

肉毒杆菌毒素(botulinum toxin, BT)是一种由肉毒杆菌产生的神经毒素蛋白质,可分为A、B、C(C1、C2)、D、E、F、G共7种类型,其中A型最易提纯、精制,毒性也最稳定,应用更为广泛。BTA主要通过抑制突出前神经末梢的乙酰胆碱和疼痛调节剂(降钙素基因相关肽和P物质)释放,使肌肉弛缓性麻痹和调节疼痛<sup>[34]</sup>。BTA注射2~3 d后开始产生效应,2周后达到最大麻痹效应,可维持4~6个月<sup>[35]</sup>。2009年,Ibarra-Hurtado等<sup>[36]</sup>首次报道了BTA在12例巨大切口疝患者中的术前应用,证实了BTA能够暂时性麻痹侧腹壁肌肉,缩小腹壁缺损,从而有助于腹壁缺损关闭。但单独BTA没有松解粘连、腹壁安全路径定位等优势<sup>[31]</sup>,且腹腔容量增加不明显,因此部分学者<sup>[37-39]</sup>将PPP和BTA联合应用于巨大切口疝等复杂腹壁疝的术前准备。Elstner等<sup>[39]</sup>认为缺损>10 cm、VIH/VAC比值>10%的原发切口疝或VIH/VAC比值>15%的复发切口疝,需要联合使用PPP与BTA进行术前准备。Bueno-Lledó等<sup>[9]</sup>认为只要切口疝的VIH/VAC比值>20%,即需进行联合术前准备。Rodriguez-Acevedo等<sup>[31]</sup>则认为腹壁缺损>15 cm、脐周缺损>9 cm或VIH/VAC比值>20%时需要联合PPP作为BTA的辅助措施进行术前准备。PPP与BTA联合应用的疝缺损范围尚无统一标准,仍需开展更多前瞻性研究进行观察。

同文献报道所述,本研究的7例患者在经PPP和BTA联合准备后,侧腹壁肌肉长度均有不同程度增加,腹壁肌肉增加的程度甚至可以和组织分离技术赋予的延长水平相比较,而没有破坏腹壁完整解剖结构<sup>[40]</sup>。此外,由于BTA持续麻痹效应,能够减轻疼痛,有利于术后切口愈合、组织长入,最大程度降低复发。

### 3.3 PPP与BTA应用的并发症及处理

PPP常见的并发症包括肩胛部疼痛、皮下气肿、腹痛腹胀、气胸、纵膈及心包积气等,但这些并发症常常通过暂时停止PPP即可缓解,无需其他干预<sup>[31,41]</sup>。也有文献<sup>[30]</sup>报道PPP后,出现呼吸功能障碍需要进行腹腔穿刺排气。因此,对于BTA的使用,应严格把握适应证、禁忌证等,密切关

注不良反应发生,防止出现意外情况。注射BTA 2~3 d后若出现咳嗽、打喷嚏无力、背部疼痛等不适,提示BTA已开始发挥作用,属于正常现象,不必特殊处理<sup>[31]</sup>。

总之,在巨大切口疝手术前进行充分的准备,对减少术后并发症非常关键。联合应用PPP和BTA可以明显增加VAC、延长侧腹壁肌肉,避免了不必要的组织结构分离,允许在较小的张力下利用腹腔镜关闭巨大切口疝缺损,减少术后ACS的发生。同时,PPP还可松解粘连、便于确定Trocar安全区域,BTA的麻痹效应有利于伤口愈合,降低复发率。

利益冲突:所有作者均声明不存在利益冲突。

#### 参考文献

- [1] Gignoux B, Bayon Y, Martin D, et al. Incidence and risk factors for incisional hernia and recurrence: retrospective analysis of the French national database[J]. *Colorectal Dis*, 2021, 23(6): 1515-1523. doi: 10.1111/codi.15581.
- [2] Rhemtulla IA, Hsu JY, Broach RB, et al. The incisional hernia epidemic: evaluation of outcomes, recurrence, and expenses using the healthcare cost and utilization project (HCUP) datasets[J]. *Hernia*, 2021, 25(6): 1667-1675. doi: 10.1007/s10029-021-02405-9.
- [3] Tashkandi A, Bueno-Lledó J, Durtette-Guzylack J, et al. Adjunct Botox to preoperative progressive pneumoperitoneum for incisional hernia with loss of domain: no additional effect but may improve outcomes[J]. *Hernia*, 2021, 25(6): 1507-1517. doi: 10.1007/s10029-021-02387-8.
- [4] Moreno IG. Chronic eventrations and large hernias; preoperative treatment by progressive pneumoperitoneum; original procedure[J]. *Surgery*, 1947, 22(6): 945-953.
- [5] Renard Y, Lardière-Deguelte S, de Mestier L, et al. Management of large incisional hernias with loss of domain: a prospective series of patients prepared by progressive preoperative pneumoperitoneum[J]. *Surgery*, 2016, 160(2): 426-435. doi: 10.1016/j.surg.2016.03.033.
- [6] Cunha LAC, Caçado ARS, Silveira CAB, et al. Management of complex hernias with loss of domain using daily and fractioned preoperative progressive pneumoperitoneum: a retrospective single-center cohort study[J]. *Hernia*, 2021, 25(6): 1499-1505. doi: 10.1007/s10029-020-02298-0.
- [7] Mancini A, Mougin N, Venchiarutti V, et al. Goni Moreno progressive preoperative pneumoperitoneum for giant hernias: a monocentric retrospective study of 162 patients[J]. *Hernia*, 2020, 24(3): 545-550. doi: 10.1007/s10029-019-02113-5.
- [8] Yurtkap Y, van Rooijen MMJ, Roels S, et al. Implementing preoperative Botulinum toxin A and progressive pneumoperitoneum through the use of an algorithm in giant ventral hernia repair[J]. *Hernia*, 2021, 25(2): 389-398. doi: 10.1007/s10029-020-02226-2.
- [9] Bueno-Lledó J, Carreño-Saenz O, Torregrosa-Gallud A, et al. Preoperative botulinum toxin and progressive pneumoperitoneum in loss of domain hernias-our first 100 cases[J]. *Front Surg*, 2020, 7: 3. doi: 10.3389/fsurg.2020.00003.
- [10] Erbguth F, Claus D, Engelhardt A, et al. Systemic effect of local botulinum toxin injections unmasks subclinical Lambert-Eaton myasthenic syndrome[J]. *J Neurol Neurosurg Psychiatry*, 1993, 56(11): 1235-1236. doi: 10.1136/jnnp.56.11.1235.
- [11] Smoot D, Zielinski M, Jenkins D, et al. Botox A injection for pain after laparoscopic ventral hernia: a case report[J]. *Pain Med*, 2011, 12(7): 1121-1123. doi: 10.1111/j.1526-4637.2011.01147.x.
- [12] 江志鹏,周大成,曾兵,等.一种切口疝缝合的创新技术:“立体”缝合[J]. *中国实用外科杂志*, 2021, 41(2): 160-163. doi: 10.19538/j.cjps.issn1005-2208.2021.02.11.
- [13] Jiang ZP, Zhou TC, Zeng B, et al. “Multidimensional” suture: an innovative technique for suture of incisional hernia[J]. *Chinese Journal of Practical Surgery*, 2021, 41(2): 160-163. doi: 10.19538/j.cjps.issn1005-2208.2021.02.11.
- [14] Slater NJ, Montgomery A, Berrevoet F, et al. Criteria for definition of a complex abdominal wall hernia[J]. *Hernia*, 2014, 18(1): 7-17. doi: 10.1007/s10029-013-1168-6.
- [15] Passot G, Villeneuve L, Sabbagh C, et al. Definition of giant ventral hernias: development of standardization through a practice survey[J]. *Int J Surg*, 2016, 28: 136-140. doi: 10.1016/j.ijso.2016.01.097.
- [16] Eriksson A, Rosenberg J, Bisgaard T. Surgical treatment for giant incisional hernia: a qualitative systematic review[J]. *Hernia*, 2014, 18(1): 31-38. doi: 10.1007/s10029-013-1066-y.
- [17] Oliver-Allen HS, Hunter C, Lee GK. Abdominal compartment syndrome as a rare complication following component separation repair: case report and review of the literature[J]. *Hernia*, 2015, 19(2): 293-299. doi: 10.1007/s10029-015-1362-9.
- [18] Angelici AM, Perotti B, Dezzi C, et al. Measurement of intra-abdominal pressure in large incisional hernia repair to prevent abdominal compartmental syndrome[J]. *G Chir*, 2016, 37(1): 31-36. doi: 10.11138/gchir.2016.37.1.031.
- [19] Kirkpatrick AW, Roberts DJ, de Waele J, et al. Intra-abdominal hypertension and the abdominal compartment syndrome: updated consensus definitions and clinical practice guidelines from the World Society of the Abdominal Compartment Syndrome[J]. *Intensive Care Med*, 2013, 39(7): 1190-1206. doi: 10.1007/s00134-013-2906-z.
- [19] Ramirez OM, Ruas E, Dellon AL. “Components separation”

- method for closure of abdominal-wall defects: an anatomic and clinical study[J]. *Plast Reconstr Surg*, 1990, 86(3): 519-526. doi: [10.1097/00006534-199009000-00023](https://doi.org/10.1097/00006534-199009000-00023).
- [20] Ramirez OM. Inception and evolution of the components separation technique: personal recollections[J]. *Clin Plast Surg*, 2006, 33(2):241-246. doi: [10.1016/j.cps.2005.12.011](https://doi.org/10.1016/j.cps.2005.12.011).
- [21] Carbonell AM, Cobb WS, Chen SM. Posterior components separation during retromuscular hernia repair[J]. *Hernia*, 2008, 12(4):359-362. doi: [10.1007/s10029-008-0356-2](https://doi.org/10.1007/s10029-008-0356-2).
- [22] Novitsky YW, Elliott HL, Orenstein SB, et al. Transversus abdominis muscle release: a novel approach to posterior component separation during complex abdominal wall reconstruction[J]. *Am J Surg*, 2012, 204(5):709-716. doi: [10.1016/j.amjsurg.2012.02.008](https://doi.org/10.1016/j.amjsurg.2012.02.008).
- [23] Blair LJ, Ross SW, Huntington CR, et al. Computed tomographic measurements predict component separation in ventral hernia repair[J]. *J Surg Res*, 2015, 199(2): 420-427. doi: [10.1016/j.jss.2015.06.033](https://doi.org/10.1016/j.jss.2015.06.033).
- [24] Zolin SJ, Fafaj A, Krpata DM. Transversus abdominis release (TAR): what are the real indications and where is the limit? [J]. *Hernia*, 2020, 24(2):333-340. doi: [10.1007/s10029-020-02150-5](https://doi.org/10.1007/s10029-020-02150-5).
- [25] Hodgkinson JD, Leo CA, Maeda Y, et al. A meta-analysis comparing open anterior component separation with posterior component separation and transversus abdominis release in the repair of midline ventral hernias[J]. *Hernia*, 2018, 22(4):617-626. doi: [10.1007/s10029-018-1757-5](https://doi.org/10.1007/s10029-018-1757-5).
- [26] Petro CC, Raigani S, Fayeizadeh M, et al. Permissible intraabdominal hypertension following complex abdominal wall reconstruction[J]. *Plast Reconstr Surg*, 2015, 136(4):868-881. doi: [10.1097/prs.0000000000001621](https://doi.org/10.1097/prs.0000000000001621).
- [27] Hadad I, Small W, Dumanian GA. Repair of massive ventral hernias with the separation of parts technique: reversal of the 'lost domain'[J]. *Am Surg*, 2009, 75(4):301-306.
- [28] Pereira-Rodriguez JA, Bravo-Salva A, Montcusí-Ventura B, et al. Early outcomes of component separation techniques: an analysis of the Spanish registry of incisional Hernia (EVEREG) [J]. *Hernia*, 2021, 25(6):1573-1580. doi: [10.1007/s10029-021-02449-x](https://doi.org/10.1007/s10029-021-02449-x).
- [29] Raynor RW, del Guercio LR. The place for pneumoperitoneum in the repair of massive hernia[J]. *World J Surg*, 1989, 13(5):581-585. doi: [10.1007/BF01658874](https://doi.org/10.1007/BF01658874).
- [30] Sabbagh C, Dumont F, Fuks D, et al. Progressive preoperative pneumoperitoneum preparation (the Goni Moreno protocol) prior to large incisional hernia surgery: volumetric, respiratory and clinical impacts. A prospective study[J]. *Hernia*, 2012, 16(1): 33-40. doi: [10.1007/s10029-011-0849-2](https://doi.org/10.1007/s10029-011-0849-2).
- [31] Rodriguez-Acevedo O, Elstner KE, Jacombs ASW, et al. Preoperative Botulinum toxin A enabling defect closure and laparoscopic repair of complex ventral hernia[J]. *Surg Endosc*, 2018, 32(2):831-839. doi: [10.1007/s00464-017-5750-3](https://doi.org/10.1007/s00464-017-5750-3).
- [32] Tanaka EY, Yoo JH, Rodrigues AJ Jr, et al. A computerized tomography scan method for calculating the hernia sac and abdominal cavity volume in complex large incisional hernia with loss of domain[J]. *Hernia*, 2010, 14(1): 63-69. doi: [10.1007/s10029-009-0560-8](https://doi.org/10.1007/s10029-009-0560-8).
- [33] Kingsnorth AN, Sivarajasingham N, Wong S, et al. Open mesh repair of incisional hernias with significant loss of domain[J]. *Ann R Coll Surg Engl*, 2004, 86(5): 363-366. doi: [10.1308/147870804236](https://doi.org/10.1308/147870804236).
- [34] Zielinski MD, Goussous N, Schiller HJ, et al. Chemical components separation with botulinum toxin A: a novel technique to improve primary fascial closure rates of the open abdomen[J]. *Hernia*, 2013, 17(1):101-107. doi: [10.1007/s10029-012-0995-1](https://doi.org/10.1007/s10029-012-0995-1).
- [35] Dressler D. Clinical applications of botulinum toxin[J]. *Curr Opin Microbiol*, 2012, 15(3):325-336. doi: [10.1016/j.mib.2012.05.012](https://doi.org/10.1016/j.mib.2012.05.012).
- [36] Ibarra-Hurtado TR, Nuño-Guzmán CM, Echeagaray-Herrera JE, et al. Use of botulinum toxin type a before abdominal wall hernia reconstruction[J]. *World J Surg*, 2009, 33(12): 2553-2556. doi: [10.1007/s00268-009-0203-3](https://doi.org/10.1007/s00268-009-0203-3).
- [37] Bueno-Lledó J, Torregrosa A, Ballester N, et al. Preoperative progressive pneumoperitoneum and botulinum toxin type A in patients with large incisional hernia[J]. *Hernia*, 2017, 21(2): 233-243. doi: [10.1007/s10029-017-1582-2](https://doi.org/10.1007/s10029-017-1582-2).
- [38] Bueno-Lledó J, Torregrosa A, Jiménez R, et al. Preoperative combination of progressive pneumoperitoneum and botulinum toxin type A in patients with loss of domain hernia[J]. *Surg Endosc*, 2018, 32(8):3599-3608. doi: [10.1007/s00464-018-6089-0](https://doi.org/10.1007/s00464-018-6089-0).
- [39] Elstner KE, Read JW, Rodriguez-Acevedo O, et al. Preoperative progressive pneumoperitoneum complementing chemical component relaxation in complex ventral hernia repair[J]. *Surg Endosc*, 2017, 31(4): 1914-1922. doi: [10.1007/s00464-016-5194-1](https://doi.org/10.1007/s00464-016-5194-1).
- [40] Farooque F, Jacombs ASW, Roussos E, et al. Preoperative abdominal muscle elongation with botulinum toxin A for complex incisional ventral hernia repair[J]. *ANZ J Surg*, 2016, 86(1/2):79-83. doi: [10.1111/ans.13258](https://doi.org/10.1111/ans.13258).
- [41] Tang FX, Ma N, Huang E, et al. Botulinum Toxin A Facilitated Laparoscopic Repair of Complex Ventral Hernia[J]. *Front Surg*, 2022, 8:803023. doi: [10.3389/fsurg.2021.803023](https://doi.org/10.3389/fsurg.2021.803023).

( 本文编辑 宋涛 )

**本文引用格式:** 汤福鑫, 马宁, 刘创雄, 等. 术前渐进性气腹联合 A 型肉毒毒素在巨大切口疝修补术中的应用价值[J]. *中国普通外科杂志*, 2022, 31(4):441-448. doi: [10.7659/j.issn.1005-6947.2022.04.005](https://doi.org/10.7659/j.issn.1005-6947.2022.04.005)

**Cite this article as:** Tang FX, Ma N, Liu CX, et al. Application value of preoperative progressive pneumoperitoneum plus botulinum toxin A injection in large incisional hernia repair[J]. *Chin J Gen Surg*, 2022, 31(4):441-448. doi: [10.7659/j.issn.1005-6947.2022.04.005](https://doi.org/10.7659/j.issn.1005-6947.2022.04.005)