



doi:10.7659/j.issn.1005-6947.2024.06.002
http://dx.doi.org/10.7659/j.issn.1005-6947.2024.06.002
China Journal of General Surgery, 2024, 33(6):876-884.

· 专题论坛 ·

主动脉脱套与TEVAR术中支架源性主动脉脱套

马韬, 符伟国

(复旦大学附属中山医院 血管外科/复旦大学血管外科研究所/国家放射与治疗临床医学研究中心, 上海200032)

摘要

急性主动脉夹层发生时内膜撕裂, 如果撕裂形态呈现为周径上的环形破口, 破口远端的内膜会脱离主动脉管壁并形成独立的内膜管腔, 这个管腔顺着血流方向塌陷之后就会形成逆行脱套病变, 即主动脉脱套。主动脉脱套发病率低, 其总数的90%发生在主动脉夹层自然病程中, 也可以是胸主动脉腔内修复术(TEVAR)的并发症。随着近年TEVAR技术的普及和手术数量的增加, 手术相关并发症的数量也逐渐增加, 但是TEVAR术中支架源性主动脉脱套(ISAI)的报道极为有限。该病作为一种罕见的夹层或并发症, 并不被大多数医生所熟知, 因此本文旨在介绍主动脉脱套和ISAI的概念、特点、诊断、分型以及处理原则与方法、注意事项, 为临床工作提供理论支持, 让更多患者受益。出现在自然病程中的主动脉脱套, 有时需要心电门控计算机断层成像血管造影或心脏超声结合使用才能明确诊断, 这种病变大部分情况下可以在开放手术中直视下修补; 但是在TEVAR手术中, 脱套病变往往只能通过数字减影血管造影发现, 而且大部分情况下优先推荐血管腔内技术修复。如果没有及时发现脱套病变, 将会出现灾难性后果。在TEVAR术中, 如果在常规造影后发现ISAI, 首先需要保留手术器械和通路。其次需要造影明确脱套分型, 根据不同的分型, 分清主动脉结构的改变, 选择不同的处理方案。ISAI分三型, I型ISAI病变局限于胸主动脉支架覆盖部位, 无需额外支架植入; II型ISAI病变位于支架覆盖远端, 但局限于胸主动脉段, 治疗上需要在胸主动脉段植入覆膜支架, 固定内膜团块, 开通真腔; III型ISAI病变位于腹主动脉段, 最危险, 对术者的手术决策和技术要求也最高。除了胸主动脉覆膜支架植入, 还需要在腹主动脉段使用裸支架固定内膜团块, 开通真腔血供。

关键词

动脉瘤, 夹层; 主动脉, 胸; 血管成形术; 手术中并发症
中图分类号: R654.3

Aortic intimal intussusception and intraoperative stent-graft-induced aortic intimal intussusception during TEVAR

MA Tao, FU Weiguo

(Department of Vascular Surgery, Zhongshan Hospital Fudan University/Institute of Vascular Surgery, Fudan University/National Clinical Research Center for Interventional Medicine, Shanghai 200032, China)

Abstract

When an acute aortic dissection occurs, the intima tears. If the tear forms a circumferential rupture, the intima distal to the tear detaches from the aortic wall and forms an independent intimal lumen. As this lumen collapses along the direction of blood flow, it creates an antegrade intimal detachment, known as

基金项目: 国家自然科学基金资助项目(82170493); 上海市卫生健康委员会科研基金资助项目(202240289)。

收稿日期: 2023-11-27; 修订日期: 2024-02-08。

作者简介: 马韬, 复旦大学附属中山医院主治医师, 主要从事主动脉夹层生物力学方面的研究。

通信作者: 符伟国, Email: fu.weiguo@zs-hospital.sh.cn

aortic intimal intussusception. Aortic intimal intussusception is rare, with 90% of cases occurring during the natural progression of an aortic dissection, but it can also be a complication of thoracic endovascular aortic repair (TEVAR). With the increasing prevalence and number of TEVAR procedures in recent years, the incidence of surgery-related complications has also risen. However, reports on intraoperative stent graft-induced aortic intimal intussusception (ISAI) during TEVAR are extremely limited. This condition, being a rare type of dissection or complication, is not well-known to most physicians. Therefore, this article aims to introduce the concept, characteristics, diagnosis, classification, treatment principles and methods, and precautions of aortic intimal intussusception and ISAI, providing theoretical support for clinical practice and benefiting more patients. Aortic intimal intussusception occurring during the natural progression of the disease sometimes requires a combination of electrocardiogram-gated computed tomography angiography or cardiac ultrasound for a definitive diagnosis. In most cases, such lesions can be repaired under direct vision during open surgery. However, during TEVAR procedures, intussusception lesions are often only detectable by digital subtraction angiography, and in most cases, endovascular techniques are recommended for repair. If the intussusception lesions are not promptly identified, catastrophic consequences can occur. During TEVAR, if ISAI is detected after routine angiography, it is crucial to first preserve the surgical instruments and access routes. Next, angiography is required to clarify the type of intussusception and to distinguish the structural changes in the aorta, selecting the appropriate treatment strategy based on the classification. ISAI is classified into three types. Type I ISAI lesion is confined to the stent-covered area of the thoracic aorta and do not require additional stent implantation. Type II ISAI lesion is located distal to the stent-covered area but are confined to the thoracic aorta. Treatment involves implanting a covered stent in the thoracic aorta to fix the intimal flap and restore true lumen patency. Type III ISAI lesion is located in the abdominal aorta, which is the most dangerous and requires the highest level of surgical decision-making and technical skill. In addition to implanting a covered stent in the thoracic aorta, a bare stent is needed in the abdominal aorta to fix the intimal flap and restore true lumen blood supply.

Key words

Aneurysm, Dissecting; Aorta, Thoracic; Angioplasty; Intraoperative Complications

CLC number: R654.3

主动脉内膜脱套或主动脉脱套是一种罕见的主动脉夹层并发症，同时也是一种罕见类型的急性主动脉夹层。它的概念首次提出于1887年，研究人员在尸检中发现了主动脉完全的环状夹层，即圆环状破口；同时也发现了主动脉内膜团块导致堵塞和器官灌注不良。现代文献中，Hufnagel等^[1]于1962年命名了主动脉内膜脱套。在此之后的英文文献报道以个案病例报道为主，总的来看主动脉脱套的发生部位主要出现在升主动脉（81%），其次降主动脉（16%），最后是主动脉弓（2%）^[2]。大部分的主动脉脱套病变（90%）出现于Stanford A型夹层的自然病程中^[2-14]。另外，作为主动脉瓣置换手术并发症出现的也有报道^[15]。主动脉脱套

在Stanford B型夹层的自然病程中也可见到，如马方综合征患者，还可见于主动脉钝伤和医源性损伤^[16]。大多数指南或综述报道并不会将此类并发症列入讨论范畴^[17]。对于Stanford B型夹层腔内治疗中的主动脉脱套英文报道目前仅有3篇^[18-20]。在2019年，我国专家张韬等^[21]共同报道了多中心的主动脉夹层腔内修复术中内膜脱套的原因及诊疗分析，该研究涵盖7例胸主动脉腔内修复术（thoracic endovascular aortic repair, TEVAR）术中主动脉脱套并发症的诊治，为国内同行提供了极具代表性的理论指导。本文介绍主动脉脱套的相关知识，回顾文献，并围绕TEVAR术中支架源性主动脉脱套（intraoperative stent graft-induced aortic

intimal intussusception, ISAI) 以及该并发症的诊治原则进行总结。笔者将通过本中心近年间的实例来介绍该致命性并发症,旨在让更多的国内医生认识到TEVAR的局限性、并发症的概念和诊疗方法,避免在今后的工作中出现灾难性的后果,从而让更多的患者获益。因ISAI发生率极低,笔者诊治和总结的病例也仅仅是对病例的简要描述,没有大宗病例报告,希望能以此文抛砖引玉。

1 自然病程中的主动脉脱套和诊断

急性主动脉夹层发生时内膜撕裂,如果撕裂形态呈现为周径上的环形破口,破口远端的内膜会脱离主动脉管壁并形成独立的内膜管腔,这个管腔顺着血流方向塌陷之后就会形成顺行脱套病

变。脱落的内膜既可以顺行脱落至主动脉腔内,也可以被逆行“吸入”左心室^[7,22-28]。所以Stanford A型夹层的主动脉脱套分两类:顺行脱套和逆行脱套(图1)^[29]。这两类病变在影像学诊断上难度较大,在临床工作中需要特别注意。首先,对于Stanford A型夹层顺行脱套,如果内膜破口位于升主动脉根部,脱套内膜片会聚集在主动脉弓部并全部或部分阻塞弓部分支动脉的血流,从而导致诸如神经系统并发症和/或双上肢血压不对称^[30]。Stanford A型夹层逆行脱套发生时,脱落的内膜可在左心室和升主动脉之间反复摆动^[30],导致主动脉瓣关闭不全和大量的主动脉反流^[31]。此外,这种情况也会导致冠状动脉口堵塞,致使心肌缺血^[32]。

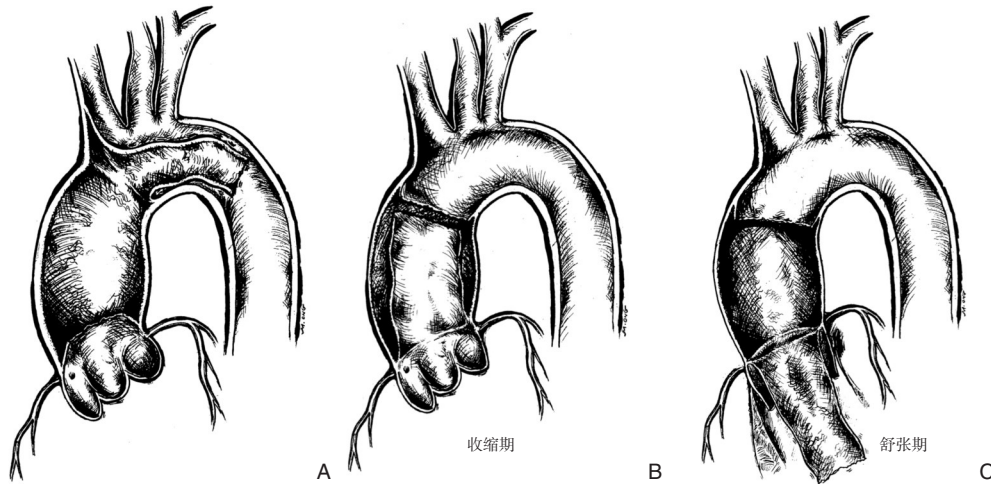


图1 主动脉脱套示意图 A: 主动脉夹层顺行脱套,内膜脱离至主动脉弓部;B-C: 主动脉夹层逆行脱套,主动脉脱套分别在心脏收缩期和舒张期两个时刻,脱套病变呈现出不同位置和形态

Figure 1 Schematic diagram of aortic intimal intussusception A: Antegrade intimal intussusception in aortic dissection, with the intima detaching to the aortic arch; B-C: Retrograde intimal intussusception in aortic dissection, with the aortic intimal intussusception appearing at different positions and in different forms during cardiac systolic and diastolic phases

对于Stanford A型夹层和顺行主动脉脱套的诊断,数字减影血管造影(digital subtraction angiography, DSA)技术难度极大,甚至无法完成,而计算机断层成像血管造影(computed tomography angiography, CTA)检查更合适^[22]。在这种情况下主动脉内膜片反转,CTA影像中往往没有升主动脉内膜片撕裂的表现,而在主动脉弓部会有内膜片脱套的表现,心脏彩超或经食道心脏彩超对此病变形态的了解也有很好的帮助^[29,33-36]。Stanford A型夹层顺行脱套在CTA图像中典型的影像学表现如下:主动脉根部和弓部有充盈缺损表现^[37],升主

动脉不可见夹层内膜片^[38-39],主动脉弓部和降主动脉会有异常的团块^[40],这种异常团块有时呈U形,会像风向标一样在主动脉管腔内摆动^[41]。跟顺行脱套不同的是,Stanford A型夹层和逆行主动脉脱套发生的时候,患者可能有大量主动脉反流和心肌缺血,诊断技术的选择也需要根据病情来调整^[42]。此时除了CTA,往往需要加做心脏彩超来明确诊断。尽管CTA可以更好的显示几何形态,但是逆行脱套在同一心动周期里会有不同的形态表现,因此只有在心电门控的配合下,才能更好地描绘收缩期和舒张期里内膜片的位置和形态。尽

管最新的MRI技术可以很好地显示主动脉管壁形态和血流分布,但是MRI检查耗时,对患者配合程度要求更高,所以并不适用于急性夹层的诊断。此类脱套病变的影像学特点有:心脏舒张期可见主动脉内膜脱垂至左心室内部,心脏收缩期可见升主动脉内膜片,即内膜片在心动周期不同时刻的反复摆动^[23,43-44]。主动脉根部增粗以及反常的摆动^[27,31],此外还可能出现主动脉反流,升主动脉增粗和心包积液^[22]。相对Stanford A型夹层脱套,Stanford B型夹层自然病程中脱套发生率极低,目前有2例病例报告^[37,45]。2例既往均因背部外伤所致夹层和主动脉脱套,其中1例行主动脉内膜剥脱并解决了腹腔脏器缺血。

2 ISAILI概念和诊断

2.1 ISAILI的概念

ISAILI的发生与TEVAR手术中和支架植入有关,而不是其他腔内操作(导管操作或球囊扩张)导致的,也不是疾病自然进程中出现的。相比远端支架源性新发破口(stent graft-induced new entry, SINE),ISAILI会导致内膜的大部分或者全部的横断面撕裂,导致更大的且更不稳定的破裂口,很可能导致TEVAR手术失败或者灾难性并发症。

主动脉脱套和ISAILI最主要的区别在于:(1)前者绝大多数出现于Stanford A型夹层的自然病程中,而ISAILI是医源性并发症,即支架输送系统或者支架金属丝导致纤薄的内膜条索或内膜片断裂。(2)主动脉脱套的定义是主动脉内膜周径上的全部断裂(圆环样破口),而ISAILI与此不同。最具代表性的就是在I型ISAILI病例中,覆膜支架输送系统导致了更大的破裂口,而破口两端的内膜仍可能还有连接,只不过在TEVAR术中不允许花费更多的时间去验证。在覆膜支架释放完成后,支架既覆盖了原发破裂口,又同时覆盖了新形成的更大破裂口,同时还在远端实现了锚定,即支架覆盖了近远端锚定区,稳定在主动脉内部,同时覆膜部分都隔绝了破裂口。ISAILI也不同于SINE,前者是术中的内膜破裂,挛缩内膜卷曲成团阻塞主动脉真腔血流;而后者通常发生在长期随访过程中,并且大部分SINE病例无症状。SINE在形成新破口之后,解剖部位一般位于内膜片外层,处于血栓化的假

腔内部。

2.2 ISAILI的诊断

在主动脉夹层自然病程中,CTA是确诊主动脉脱套的金标准,检查中不仅可以明确夹层分型,也可以充分了解主动脉病变的几何形态。相对而言,ISAILI的诊断首选DSA,标准的造影方法以及仔细地阅片对ISAILI的诊断非常重要。如果术中沒有及时发现ISAILI,手术结束后,腔内器械通路撤出之后想再重新使用腔内技术开通卷曲的内膜团块的难度极大。因此,在TEVAR术中,植入支架之后,常规胸腹主动脉各节段的造影需按规范完成,并仔细阅片。ISAILI典型的DSA表现是覆膜支架远端的内膜团块形成,因此主动脉真腔的血流受阻,内脏血流同时受累。此外,ISAILI出现后,主动脉的另一典型造影特征是真假腔血流的重新分布,即真腔消失,ISAILI近端主动脉管腔明显增粗。其他的检查方法对于ISAILI诊断虽有帮助,但是不利于及时治疗。因为ISAILI一旦发生,内脏和下肢均处于缺血状态,此时优先选择简便易行的检查,诸如腔内超声和CT虽然可以对管腔和内膜片结构提供更好的形态学信息,但是更耗时,故不建议使用。

根据DSA影像学特点明确ISAILI分型,分清主动脉结构的改变,选择不同的处理方案。I型ISAILI:(1)透视下输送系统不按照原有内膜片轨迹走形,有突破内膜片的表现,即外移至主动脉大弯侧方向;(2)DSA结果提示输送系统导入后内膜片破裂;(3)主动脉真腔和真腔供血的分支内血流通畅。II型ISAILI:(1)覆膜支架末端扩张程度超过了原有内膜片的边界,远端锚定区消失,支架远端犹如“风向标”效应“悬空”在主动脉管腔内部;(2)支架导入或释放之后的造影可见内膜片萎陷;(3)主动脉真腔和真腔供血的分支内血流受阻或消失,萎陷的内膜团块位于支架远端但在腹腔干动脉近端。III型ISAILI:(1)第1枚覆膜支架释放后,支架在位通畅;(2)造影或透视发现支架末端节段扩张程度超过真腔的界限;(3)主动脉造影可见内膜片萎陷,内膜团块位于腹腔干动脉远端;(4)主动脉真腔和真腔供血分支动脉内部血流减少或消失,而胸主动脉假腔血流增加,管腔增粗(图2)。

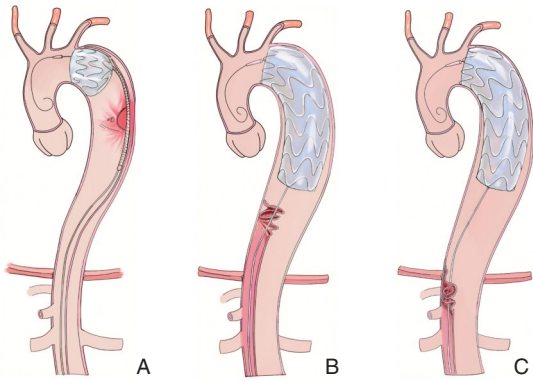


图2 三种类型的ISaII示意图 A: I型ISaII, 支架导入时或释放时, 支架和输送系统导致脱套, 但支架释放完成后将脱套病变完整覆盖; B: II型ISaII, 真腔结构消失, 主动脉增粗, 假腔扩张, 内膜团块位于膈肌上方水平; C: III型ISaII, 真腔结构消失, 主动脉增粗, 假腔扩张, 内膜团块位于膈肌下方水平

Figure 2 Schematic diagram of the three types of ISaII
A: Type I ISaII - The stent or delivery system causes intimal intussusception during stent introduction or release, but the detachment lesion is completely covered after stent deployment; B: Type II ISaII - The true lumen structure disappears, the aorta enlarges, and the false lumen expands, with the intimal flap located above the diaphragm; C: Type III ISaII - The true lumen structure disappears, the aorta enlarges, and the false lumen expands, with the intimal flap located below the diaphragm

3 ISaII的治疗

治疗上, I型ISaII的病变出现后, 如果造影证实第1枚覆膜支架近远端锚定区均充分, 支架定位和形态均满意, 则无需多余支架植入。对于II型ISaII, 首选方法是再将覆膜支架植入胸主动脉, 跟第1枚支架衔接, 重建胸主动脉真腔血流的同时固定挛缩内膜团块。如果此时没有合适尺寸的覆膜支架, 可以使用裸支架植入。优先选择覆膜支架的原因有如下两点: (1) 覆膜支架可以隔绝内膜离断后留下的间隙, 促进假腔血栓形成; (2) 相对裸支架而言, 覆膜支架尺寸更大, 释放时定位更准确, 可以更好地衔接原有支架和固定内膜团块, 从而减少支架移位和内漏风险。基于此, 只要胸主动脉、腹主动脉和分支的血流恢复, 支架和脱套团块稳定, 则无需额外支架植入(图3-5)。需要注意的是, II型ISaII可以转化为III型, 这时需要按照III型病变的治疗方法进行。

III型ISaII病变最为复杂, 主动脉内膜撕脱距

离更长, 修复难度最大。在胸主动脉段, 原则上依然优先选择覆膜支架隔绝假腔, 桥接真腔血流; 在腹主动脉段, 使用裸支架固定脱落的内膜团块和开通真腔。如果腹主动脉在裸支架植入后血流恢复, 而且分支动脉血流同时恢复, 则不需要额外在分支动脉内植入支架, 否则仍需要继续尝试开通内脏或下肢动脉血供。在III型病变形形成后, 第1枚主动脉覆膜支架远端锚定区消失, 第2枚支架的锚定部位管腔尺寸变大, 内膜团块挛缩至膈肌以下水平。因此, 第2枚覆膜支架的固定完全依赖于其跟第1枚覆膜支架的重叠释放。但是, 在释放之后往往会给术者带来更大的困扰和压力, 因为此时胸主动脉段真腔血流尚未恢复。须在腹主动脉段植入裸支架, 开通挛缩的内膜团块, 真腔血流才能恢复。在此部位植入裸支架, 尺寸不宜过大, 以避免大尺寸支架植入造成扩张, 导致不稳定的ISaII病变继续撕裂, 同时也要避免球囊扩张该处病变(图6)。在此情形下, 腹主动脉分支的血供既可以由真腔, 也可以假腔供血。

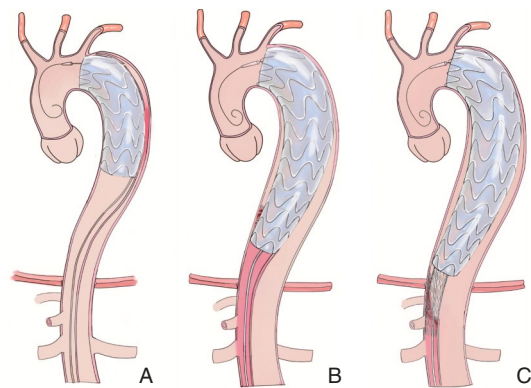


图3 ISaII处理示意图 A: I型ISaII发生后, 近远端锚定区均充分, 支架在位, 无需再次植入支架; B: II型ISaII, 胸主动脉覆膜支架植入开通真腔, 覆盖内膜团块; C: III型ISaII, 胸主动脉覆膜支架植入开通真腔, 重建真腔血流, 腹主动脉段裸支架植入, 开通真腔并固定内膜团块

Figure 3 Schematic diagram of ISaII management
A: Type I ISaII - After occurrence, both proximal and distal landing zones are adequate, and the stent is in place without the need for additional stent implantation; B: Type II ISaII - A covered stent is implanted in the thoracic aorta to open the true lumen and cover the intimal flap; C: Type III ISaII - A covered stent is implanted in the thoracic aorta to open the true lumen and restore true lumen blood flow, and a bare stent is implanted in the abdominal aorta to open the true lumen and fix the intimal flap

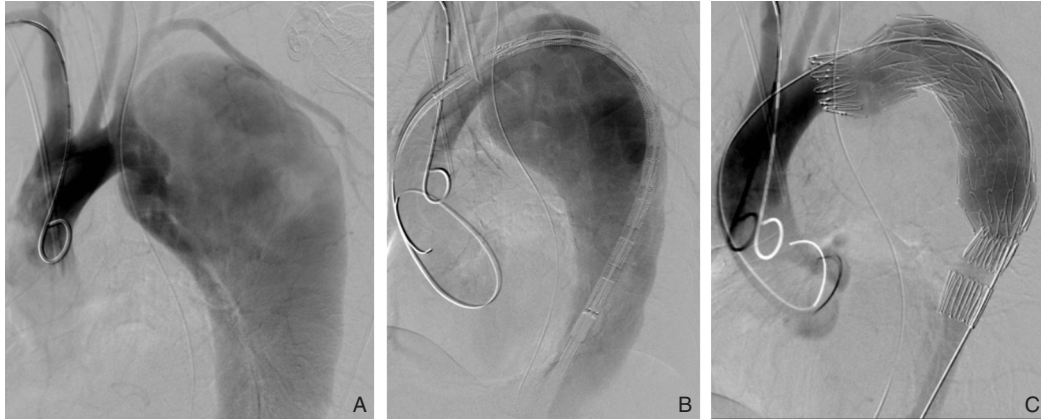


图4 I型ISAI病例 A: 支架植入前造影图像,可见原发破裂口,真假腔形态和内膜片位置;B: 支架输送系统导入后,造影见内膜片结构消失,输送系统突出到假腔内部,I型ISAI发生;C: 支架释放之后,造影见ISAI被支架覆盖,近远端锚定区充足,真腔血流通畅,ISAI无进展

Figure 4 Type I ISAI case A: Angiographic image before stent implantation showing the primary tear, the morphology of the true and false lumens, and the position of the intimal flap; B: After the stent delivery system is introduced, angiography shows the disappearance of the intimal flap structure, with the delivery system protruding into the false lumen, indicating the occurrence of type I ISAI; C: After stent deployment, angiography shows the ISAI covered by the stent, with sufficient proximal and distal landing zones, unobstructed true lumen blood flow, and no progression of ISAI

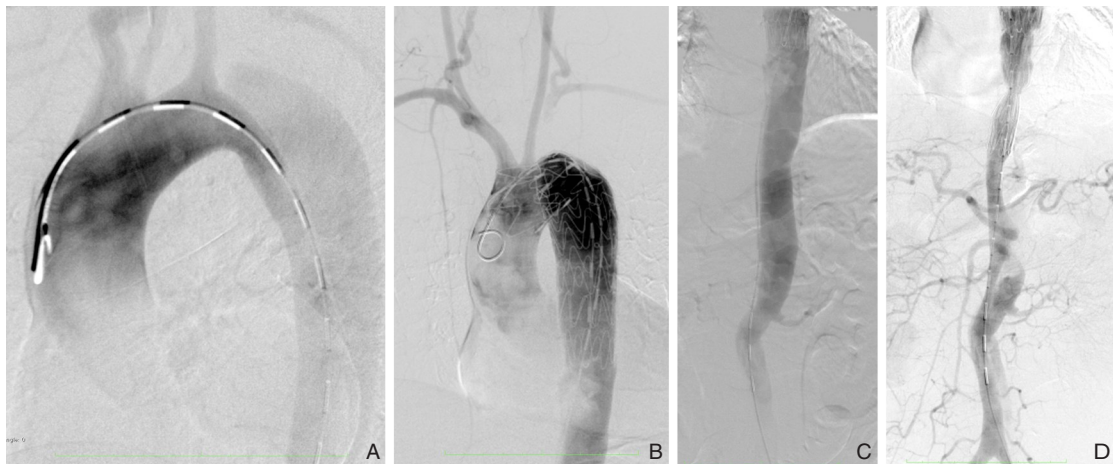

图5 II型ISAI病例 A: 支架植入前造影图像,可见破口,真假腔形态和内膜片位置;B: 支架释放后造影,支架远端可见内膜团块,真腔结构消失,II型ISAI发生;C: 支架远端胸腹主动脉造影见II型ISAI发生,真腔供血脏器均缺血,仅有假腔通畅,且主动脉增粗;D: 第2枚胸主动脉支架植入后造影,内膜团块被覆盖,真腔血流恢复,内脏动脉血流恢复,ISAI无进展

Figure 5 Type II ISAI case A: Angiographic image before stent implantation showing the tear, the morphology of the true and false lumens, and the position of the intimal flap; B: Angiography after stent deployment shows an intimal flap at the distal end of the stent, disappearance of the true lumen structure, indicating the occurrence of type II ISAI; C: Angiography of the thoracoabdominal aorta at the distal end of the stent shows the occurrence of type II ISAI, with ischemia of organs supplied by the true lumen, only the false lumen remaining patent, and an enlarged aorta; D: Angiography after implantation of a second thoracic aortic stent shows the intimal flap covered, restoration of true lumen blood flow, resumption of blood flow to visceral arteries, and no progression of ISAI

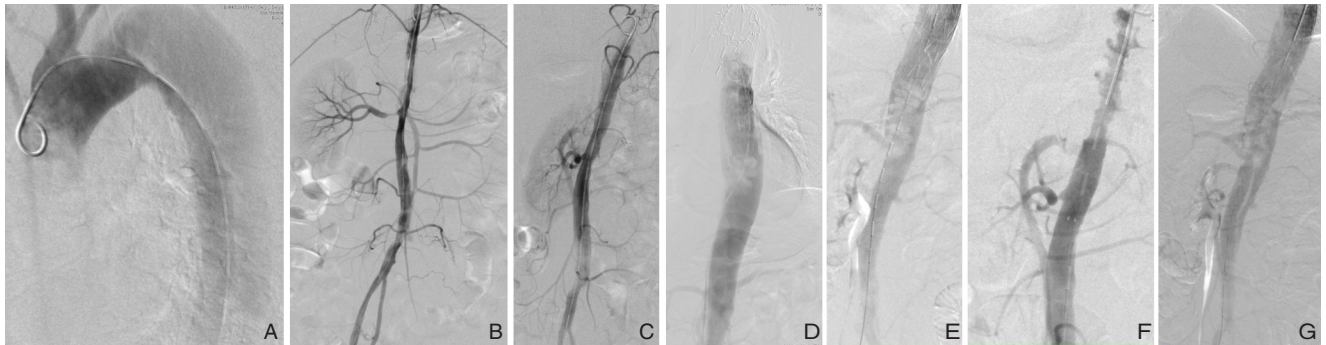

图6 III型ISAI病例 A-C: 支架植入前造影图像, 可见破口, 真假腔形态和内膜片位置; D: 支架释放后造影, 支架远端可见内膜团块, 真腔结构消失, II型ISAI发生; E: 第2枚覆膜支架植入后见脱套病变继续向远端移动, 并且降至膈肌以下水平; F-G: 多枚裸支架跨膈肌水平释放至肾下主动脉, 固定内膜团块, 开通真腔血流; 同期肠系膜上动脉支架植入解决肠缺血

Figure 6 Type III ISAI case A-C: Angiographic images before stent implantation showing the tear, the morphology of the true and false lumens, and the position of the intimal flap; D: Angiography after stent deployment shows an intimal flap at the distal end of the stent, disappearance of the true lumen structure, indicating the occurrence of type II ISAI; E: After implantation of a second covered stent, the intussusception lesion continues to move distally, reaching below the diaphragm level; F-G: Multiple bare stents are deployed across the diaphragm level to the infrarenal aorta, fixing the intimal flap and restoring true lumen blood flow; simultaneously, a superior mesenteric artery stent is implanted to solve the mesenteric ischemia

在腔内修复 ISAI 病变之后, 需特殊关注内脏缺血表现和缺血再灌注征象, 同时也需要关注相关的实验室检查结果。如果仍有缺血表现, 可充分评估腔内治疗的可行性, 如果没有条件, 需要开放手术纠正缺血。目前可参考的 TEVAR 术中主动脉脱套研究数量极为有限, 极具指导意义的如下: Wu 等^[18]曾报道过 1 例开放手术成功救治外院主动脉脱套, 腹腔脏器和下肢缺血的病例。此病例经过评估后已无腔内开通条件, 所以采取了主动脉内膜剥脱和髂动脉支架植入的方式来重建真腔血流, 纠正缺血。前述张韬等^[21]研究中, 均采用了腔内修复的方法救治。笔者中心处理的 ISAI 病例均在出现后主动脉脱套即刻开始腔内治疗, 而且均成功救治。出院后需密切随访, 观察支架位置、通畅性以及分支动脉通畅性。这些方法和处理原则可以为其他单位的临床工作提供参考。

4 ISAI 的预防

导致 ISAI 的原因尚不明确, 除自然病程中可见以外, 其他合并症和危险因素也可导致主动脉脱套, 例如患者合并马方综合征、高血压和可卡因滥用, 以及医源性损伤^[21]。笔者认为 ISAI 是主动脉覆膜支架诱发的内膜损伤。在笔者诊治的病

例中, 平均的 ISAI 远端放大比率是 110.69%, 这个数值并没有显著高于非 ISAI 病例的远端放大比率, 估计致病原因很可能跟 TEVAR 术后逆撕 A 型夹层类似。笔者在工作中注意到, 如果降主动脉有破口, 而支架远端锚定区也在破口周围, 术中极易出现 ISAI。假如术前评估可知支架远端锚定区位于远端破口处, 可以采取限制性支架植入的方法, 隔绝远端破口保护该处内膜。其他的致病因素可能跟主动脉弓形态和真腔狭窄有关, 因为在这些情况下, 器械导入过程极为困难, 反复尝试导入和更大的推送力量很可能撕裂血管内膜。

综上, 对主动脉脱套的了解有助于更好地理解 ISAI 并发症, 该并发症的出现可能致命。术者需要熟悉主动脉脱套的概念和影像学表现, 才能在术中遇到此类并发症时沉着应对。腔内修复是 ISAI 的首选治疗方法。如果腔内治疗失败, 需要立即开放手术纠正脏器缺血, 以避免更严重的后果出现。

利益冲突: 所有作者均声明不存在利益冲突。

作者贡献声明: 马韬、符伟国共同负责研究设计, 数据收集和分析, 文章写作和修改。

参考文献

- [1] Hufnagel CA, Conrad PW. Intimo-intimal intussusception in dissecting aneurysms[J]. *Am J Surg*, 1962, 103: 727-731. doi: 10.1016/0002-9610(62)90255-6.
- [2] Roberts WC, Kapoor P, Main ML, et al. Acute aortic dissection with intussusception of the partition between the true and false channels leading to near total aortic occlusion (true aortic stenosis)[J]. *Am J Cardiol*, 2017, 119(2): 340-344. doi: 10.1016/j.amjcard.2016.09.029.
- [3] von Aspern K, Etz CD, Lehmkuhl L, et al. A rare pattern of acute type A aortic dissection: circumferential intimal invagination[J]. *Thorac Cardiovasc Surg*, 2012, 60(8): 552-554. doi: 10.1055/s-0032-1322615.
- [4] Armour T, Armour S, Reddy P, et al. Type A dissection involving intimo-intimal intussusception through the aortic valve[J]. *AA Case Rep*, 2015, 5(2):21-24. doi:10.1213/XAA.0000000000000159.
- [5] Ciulla MM, Vivona P, Lemos A, et al. Atrial fibrillation, an epiphenomenon of acute Stanford type-a aortic dissection with suspected intimo-intimal intussusception[J]. *Clin Case Rep*, 2018, 6(9):1791-1794. doi:10.1002/ccr3.1701.
- [6] Aranda-Michel E, Bianco V, Kilic A, et al. Acute type A aortic dissection with complete intimal intussusception into the descending aorta[J]. *J Card Surg*, 2020, 35(7): 1626-1627. doi: 10.1111/jocs.14599.
- [7] Ibrahim M, Rashid J, Kurtz SC, et al. The telescoping aorta: a case of circumferential aortic dissection with intimo-intimal intussusception into the left ventricle[J]. *BMJ Case Rep*, 2017, 2017:bcr2017221399. doi:10.1136/bcr-2017-221399.
- [8] Ito Y, Nakamura Y, Kuroda M, et al. Valve-sparing aortic root replacement for extremely localized circumferential aortic dissection associated with intimo-intimal intussusception[J]. *Gen Thorac Cardiovasc Surg*, 2018, 66(5): 294-298. doi: 10.1007/s11748-017-0806-9.
- [9] Nakamura R, Honda K, Yuzaki M, et al. Severe aortic regurgitation with intimal intussusception secondary to Debakey type I aortic dissection[J]. *Echocardiography*, 2020, 37(4): 652-653. doi: 10.1111/echo.14640.
- [10] Nishioka N, Morimoto N, Yoshida M, et al. Intimointimal intussusception in both the proximal and distal ascending aorta: a rare clinical form of acute type A aortic dissection[J]. *Eur J Cardiothorac Surg*, 2014, 45(5):947. doi:10.1093/ejcts/ezt464.
- [11] Rajesh GN, Sajeer K, Anishkumar N, et al. Intimo-intimal intussusception-circumferential aortic dissection: a rare mechanism of severe acute aortic regurgitation[J]. *J Echocardiogr*, 2014, 12(3): 118-119. doi:10.1007/s12574-014-0216-2.
- [12] Sanchez Oro R, Ibáñez Muñoz D, Salceda Artola J, et al. Circumferential type A aortic dissection with intimal intussusception[J]. *J Cardiovasc Comput Tomogr*, 2015, 9(5):459-460. doi:10.1016/j.jcct.2015.02.005.
- [13] Lannon C, Arunachalam P, El Nihum LI, et al. Type A aortic dissection with antegrade intimointimal intussusception[J]. *Methodist Debaquey Cardiovasc J*, 2023, 19(1):26-31. doi:10.14797/mdcvj.1210.
- [14] Yanase Y, Ohkawa A, Inoue S, et al. Stanford type A acute aortic dissection with intimal intussusception[J]. *Ann Thorac Cardiovasc Surg*, 2020, 26(1):51-54. doi:10.5761/atcs.cr.18-00015.
- [15] Jubran A, Flugelman MY, Khader N, et al. Aortic root intussusception during transcatheter aortic valve replacement[J]. *JACC Cardiovasc Interv*, 2016, 9(19): e195-e196. doi: 10.1016/j.jcin.2016.06.053.
- [16] Kalsi R, Drucker CB, Salazar JH, et al. Blunt multifocal aortic injury with abdominal aortic intimointimal intussusception[J]. *J Vasc Surg Cases Innov Tech*, 2018, 4(1): 37-40. doi: 10.1016/j.jvscit.2017.11.007.
- [17] 王曦,舒畅. 腹主动脉夹层的诊断和治疗现状[J]. *中国普通外科杂志*, 2020, 29(6): 649-653. doi: 10.7659/j.issn.1005-6947.2020.06.002.
- Wang T, Shu C. Current status of diagnosis and treatment of abdominal aortic dissection[J]. *China Journal of General Surgery*, 2020, 29(6):649-653. doi:10.7659/j.issn.1005-6947.2020.06.002.
- [18] Wu ZY, Li P, Wang JY, et al. Aortic intimal intussusception during acute type B aortic dissection endovascular repair[J]. *Ann Transl Med*, 2019, 7(22):700. doi:atm.2019.10.52.
- [19] Havelka GE, Tomita TM, Malaisrie SC, et al. Two cases of aortic intimal intussusception during endovascular repair of an acute type B dissection[J]. *J Endovasc Ther*, 2016, 23(3): 521-528. doi: 10.1177/1526602816644917.
- [20] Li JH, Li QM, Shu C. Aortic intimal intussusception induced by stent-graft during endovascular repair of acute type B aortic dissection[J]. *Eur Heart J*, 2023, 44(45): 4813. doi: 10.1093/eurheartj/ehad604.
- [21] 张韬,张学民,李伟,等. 主动脉夹层腔内修复术中内膜脱套的原因及诊疗分析[J]. *中华全科医师杂志*, 2019, 18(2):170-174. doi: 10.3760/cma.j.issn.1671-7368.2019.02.015.
- Zhang T, Zhang XM, Li W, et al. Causes and treatment of intimo-intimal intussusception in endovascular repair of aortic dissecting aneurysms[J]. *Chinese Journal of General Practitioners*, 2019, 18(2):170-174. doi:10.3760/cma.j.issn.1671-7368.2019.02.015.
- [22] Kotsuka Y, Ezure M, Kawauchi M, et al. Swinging motion of intimal flap through the aortic valve in acute aortic dissection[J]. *J Cardiovasc Surg*, 2000, 41(3):395-397.
- [23] Lajevardi SS, Sian KR, Ward M, et al. Circumferential intimal tear in type A aortic dissection with intimo-intimal intussusception into

- left ventricle and left main coronary artery occlusion[J]. *J Thorac Cardiovasc Surg*, 2012, 144(2): e21-e23. doi: 10.1016/j.jtcvs.2012.05.010.
- [24] Morimoto N, Okada K, Okita Y. Aortic regurgitation and coronary malperfusion secondary to intimo-intimal intussusception into the left ventricle in acute aortic dissection[J]. *Eur J Cardiothorac Surg*, 2009, 36(1):189-190. doi:10.1016/j.ejcts.2009.03.015.
- [25] Ozer O, Davutoglu V, Burma O, et al. A dreadful sign of aortic dissection: aortic intimo-intimal intussusception with prominent intimal flap prolapsing into the left ventricular apex[J]. *Vasa*, 2009, 38(2):181-183. doi:10.1024/0301-1526.38.2.181.
- [26] Rosenzweig BP, Goldstein S, Sherrid M, et al. Aortic dissection with flap prolapse into the left ventricle[J]. *Am J Cardiol*, 1996, 77(2):214-216. doi:10.1016/s0002-9149(96)90605-0.
- [27] Yamabi H, Imanaka K, Sato H, et al. Extremely localized aortic dissection and intussusception of the intimal flap into the left ventricle[J]. *Ann Thorac Cardiovasc Surg*, 2011, 17(4): 431-433. doi:10.5761/atcs.cr.10.01594.
- [28] Yamagishi T, Kashiura M, Nakata K, et al. A case of circumferential type A aortic dissection with intimal intussusception diagnosed using repeat transthoracic echocardiography examination[J]. *Acute Med Surg*, 2017, 4(3): 322-325. doi:10.1002/ams2.262.
- [29] Sanders LHA, Newman MAJ, Gara KL, et al. Radiological diagnosis and classification of antegrade and retrograde Stanford type A intimal intussusception[J]. *Int J Cardiovasc Imaging*, 2007, 23(5):659-665. doi:10.1007/s10554-006-9182-8.
- [30] Vural U, Balci AY, Aglar AA, et al. Unusual complication of aortic dissections: intimo-intimal intussusception[J]. *Cardiovasc J Afr*, 2015, 26(4):e15-e18. doi:10.5830/CVJA-2015-029.
- [31] Touati G, Carmi D, Trojette F, et al. Intimo-intimal intussusception: a rare clinical form of aortic dissection[J]. *Eur J Cardiothorac Surg*, 2003, 23(1):119-121. doi:10.1016/s1010-7940(02)00674-7.
- [32] Kızıltan HT, Tıraş M, İdem A, et al. Intimal intussusception in aortic dissection and coexisting coronary artery disease[J]. *Ann Thorac Surg*, 2014, 97(2): 698-700. doi: 10.1016/j.athoracsur.2013.05.110.
- [33] Niino T, Unosawa S, Shimura K. Stanford type A aortic dissection with intimal intussusception[J]. *Gen Thorac Cardiovasc Surg*, 2012, 60(9):578-580. doi:10.1007/s11748-012-0051-1.
- [34] Thunberg CA, Ramakrishna H. Echocardiographic detection of intimo-intimal intussusception in a patient with acute Stanford type A aortic dissection[J]. *Ann Card Anaesth*, 2015, 18(2):227-230. doi: 10.4103/0971-9784.154481.
- [35] Sraow JS, Dessler KB, Benchimol A, et al. Two-dimensional echocardiographic recognition of an aortic intimal flap prolapsing into the left ventricular outflow tract[J]. *J Am Coll Cardiol*, 1984, 4(1):180-182. doi:10.1016/s0735-1097(84)80338-1.
- [36] Wong SS. Acute aortic dissection with intimal intussusception: transesophageal echocardiographic appearances[J]. *Can J Anaesth*, 2008, 55(10):715. doi:10.1007/BF03017748.
- [37] Kim HJ, Chung HY, Choi JY. Intimointimal intussusception in traumatic type B aortic dissection: CT and aortographic findings[J]. *Clin Radiol*, 2000, 55(6):487-489. doi:10.1053/crad.2000.0095.
- [38] Nelsen KM, Spizarny DL, Kastan DJ. Intimointimal intussusception in aortic dissection: CT diagnosis[J]. *AJR Am J Roentgenol*, 1994, 162(4):813-814. doi:10.2214/ajr.162.4.8140996.
- [39] Ishii H, Nakamura K, Yano M, et al. Circumferential dissection of the ascending aorta "intimo-intimal intussusception" [J]. *Ann Vasc Dis*, 2012, 5(4):466-468. doi:10.3400/avd.cr.11.00096.
- [40] Goldberg SP, Sanders C, Nanda NC, et al. Aortic dissection with intimal intussusception: diagnosis and management[J]. *J Cardiovasc Surg (Torino)*, 2000, 41(4):613-615.
- [41] Karabulut N, Goodman LR, Olinger GN. CT diagnosis of an unusual aortic dissection with intimointimal intussusception: the wind sock sign[J]. *J Comput Assist Tomogr*, 1998, 22(5):692-693. doi:10.1097/00004728-199809000-00004.
- [42] Pan H, Sun W. Stanford type A acute aortic dissection with proximal intimo-intimal intussusception: a case report and literature review[J]. *J Cardiothorac Surg*, 2021, 16(1): 201. doi: 10.1186/s13019-021-01581-0.
- [43] Massetti M, Neri E, Babatasi G, et al. Flap suffocation: an uncommon mechanism of coronary malperfusion in acute type A dissection[J]. *J Thorac Cardiovasc Surg*, 2003, 125(6):1548-1550. doi:10.1016/s0022-5223(03)00047-3.
- [44] Neri E, Capannini G, Carone E, et al. The missing flap: considerations about a case of aortic intussusception[J]. *J Thorac Cardiovasc Surg*, 1999, 117(4):829-830. doi:10.1016/S0022-5223(99)70309-0.
- [45] Kim SY, Hwang HY, Lee W, et al. Aortic intimointimal intussusception in chronic type B dissection causing dynamic obstruction of visceral arteries[J]. *J Thorac Cardiovasc Surg*, 2015, 150(3): e33-e35. doi:10.1016/j.jtcvs.2015.05.033.

(本文编辑 姜晖)

本文引用格式:马韬,符伟国.主动脉脱套与TEVAR术中支架源性主动脉脱套[J].中国普通外科杂志,2024,33(6):876-884. doi: 10.7659/j.issn.1005-6947.2024.06.002

Cite this article as: Ma T, Fu WG. Aortic intimal intussusception and intraoperative stent-graft-induced aortic intimal intussusception during TEVAR[J]. *Chin J Gen Surg*, 2024, 33(6): 876-884. doi: 10.7659/j.issn.1005-6947.2024.06.002