



doi:10.7659/j.issn.1005-6947.2024.06.004
http://dx.doi.org/10.7659/j.issn.1005-6947.2024.06.004
China Journal of General Surgery, 2024, 33(6):894-900.

· 专题研究 ·

新型全腔内经股动脉三分支覆膜支架系统治疗主动脉弓部病变的FIM研究

左健, 刘金成, 俞世强, 易蔚, 张静隆, 陈佳, 李超, 孙子兰, 李子林

(中国人民解放军空军军医大学第一附属医院 心血管外科, 陕西 西安 710032)

摘要

背景与目的: 目前, 主动脉弓部病变还是以常规全弓置换为主要治疗手段。常规全弓置换术需要在开胸及深低温体外循环状态下完成, 手术时间可达10余小时, 是名副其实的“血战、夜战、死战”手术。由于主动脉弓部特殊的解剖结构, 使其长期被视为腔内治疗的“禁区”。虽然主动脉弓部腔内技术日新月异, 但其瓶颈问题始终无法突破, 目前仍很难在临床上广泛应用。本文报告笔者中心采用一款新型全腔内经股动脉三分支覆膜支架系统治疗主动脉弓部病变的first-in-man (FIM) 研究结果, 初步评价其应用效果与安全性。

方法: 分析2023年10月—2023年12月中国人民解放军空军军医大学第一附属医院采用新型全腔内经股动脉三分支覆膜支架系统为3例主动脉弓部存在病变的患者实施治疗的临床结果。采集患者基本信息及病变特点、术中相关指标、术后主动脉弓部修复及相关并发症情况。

结果: 3例患者均为男性, 年龄50~74岁。手术全部成功, 无短期术后并发症及死亡。3例患者包括主动脉弓部夹层动脉瘤1例, 主动脉弓部瘤伴溃疡2例; 其中2例患者因胸痛就诊, 1例为体检发现。3例患者均合并高血压, 合并糖尿病1例。2例患者病变位于1~3区, 累及左颈总动脉; 1例患者病变位于0~3区, 累及无名动脉和左颈总动脉。平均手术时间125 min。1例带管入重症监护室 (ICU), 其余2例均于手术室内拔管。术中无脑部缺血过程, 未出现心脑血管并发症。术中支架均由股动脉入路导入, 支架植入顺利, 术中行数字减影血管造影提示支架位置、形态良好, 血流通畅, 病变区域完全隔绝, 无内漏及分支动脉狭窄的不良事件出现。ICU平均停留时间31 h。术后复查主动脉血管成像显示主体及分支支架位置良好, 瘤体隔绝良好, 无内漏及分支血管狭窄闭塞等情况。术后无心脑血管并发症出现。

结论: 应用新型全腔内经股动脉三分支覆膜支架系统治疗主动脉弓部病变, 术中无脑缺血过程, 输送系统均由股动脉入路, 操作更加简便, 创伤进一步减小。手术过程平顺, 手术效果良好, 术后短期疗效满意, 具有较好的临床应用前景。

关键词

主动脉疾病; 主动脉, 胸; 血管内操作; 支架; 三分支重建

中图分类号: R654.3

基金项目: 国家重点研发计划基金资助项目 (2016YFC1301900, 2016YFC1301901)。

收稿日期: 2024-01-15; **修订日期:** 2024-03-01。

作者简介: 左健, 中国人民解放军空军军医大学第一附属医院主任医师, 主要从事主动脉疾病介入治疗方面的研究。

通信作者: 李子林, Email: lizhuoyuanbb@163.com

First-in-man study of a new femoral endovascular access supra-arch branched stent graft for the treatment of aortic arch disease

ZUO Jian, LIU Jincheng, YU Shiqiang, YI Wei, ZHANG Jinglong, CHEN Jia, LI Chao, SUN Zilan, LI Zilin

(Department of Cardiovascular Surgery, the First Affiliated Hospital of Air Force Military Medical University, Xi'an 710032, China)

Abstract

Background and Aims: Currently, conventional total arch replacement remains the main treatment for lesions involving the aortic arch. Conventional total arch replacement requires completion under the open chest and cardiopulmonary bypass, with a surgical duration of over 10 hours, earning it the title of a "bloody, night-long, life-or-death" surgery. Due to the unique anatomical structure of the aortic arch, it has long been considered a "forbidden zone" for endovascular treatment. Although intra-aortic techniques for the aortic arch are advancing rapidly, the bottleneck issue still needs to be solved, making it difficult to be widely applied in clinical practice. Here, the authors report the results of the first-in-man (FIM) study of a new femoral endovascular access supra-arch branched stent graft for treating aortic arch lesions to evaluate its application effectiveness and safety preliminarily.

Methods: The clinical results of 3 patients with aortic arch lesions treated using the femoral endovascular access supra-arch branched stent graft at the First Affiliated Hospital of Air Force Medical University from October 2023 to December 2023 were analyzed. Patient baseline information, lesion characteristics, intraoperative parameters, postoperative aortic arch repair, and related complications were collected.

Results: All three patients were male, aged between 50 and 74. All surgeries were successful without short-term postoperative complications or deaths. The three patients included one case of aortic arch coarctation aneurysm and two cases of aortic arch aneurysm with ulceration; two of them presented with chest pain, and one was incidentally found during physical examination. All three patients had concomitant hypertension, and one had diabetes. The lesions in two patients were located in zones 1–3, involving the left common carotid artery, and in one patient, the lesion was located in zones 0–3, involving the innominate artery and the left common carotid artery. The average operative time was 125 min. One patient was admitted to the intensive care unit (ICU) with catheter indwelling, while the remaining two had their catheters removed in the operating room. There was no cerebral ischemia process, and no cardiovascular or cerebrovascular complications occurred during the operation. The stents were all introduced via the femoral artery route, and the implantation was smooth. Intraoperative digital subtraction angiography showed excellent position and shape of the stent graft with good patency, complete isolation of the lesion area, and no adverse events such as endoleak or branch artery stenosis. The average length of ICU stay was 31 h. Postoperative reexamination of aortic vascular imaging showed good positions of the main and branch stents, good isolation of the lesions, and no endoleak or branch vessel stenosis or occlusion. There were no postoperative cardiovascular and cerebrovascular complications.

Conclusion: Applying this new femoral endovascular access supra-arch branched stent graft to treat aortic arch lesions results in no cerebral ischemia during the operation. Moreover, the delivery system is accessed via the femoral artery route, making the procedure more straightforward and reducing trauma further. The surgery proceeds uneventfully, with good outcomes, and the short-term postoperative efficacy is satisfactory, indicating promising clinical application prospects.

Key words Aortic Diseases; Aorta, Thoracic; Endovascular Procedures; Stents; Three-Branch Reconstruction

CLC number: R654.3

目前, 开放主动脉弓手术仍是心脏外科中最复杂的手术之一^[1-2]。常规的处理办法是传统开放手术, 但此类手术创伤大、手术时间长、病死率高^[3-4]。由于主动脉弓部特殊的解剖结构, 使其长期被视为腔内治疗的“禁区”^[5-6]。近年来, 我国主动脉腔内微创技术逐渐成熟, 主动脉弓部微创化技术和产品也层出不穷。当前, 体外/体内开窗技术临床应用较广^[7-8]。但是, 阻碍弓部分支血流、内漏等问题仍无法得到根本解决^[9]。目前, 各类型商品化弓部介入三分支支架均处于临床试验阶段, 也获得了较好的临床效果^[10]。中国人民解放军空军军医大学第一附属医院心血管外科采用一款新型全腔内经股动脉三分支覆膜支架系统(中国杭州创心医学)(以下简称自适应三分支介入覆膜支架)处理主动脉弓部病变。该产品实现了分支支架均由股动脉经皮介入植入及解剖性矫治主动脉弓部病变(图1)。该产品得到中国人民解放军空军军医大学第一附属医院医学伦理审查委员会批准(许可证号: KY20232010-F-1), 为首次应用于临床(first-in-man, FIM)。同时, 经教育部科技查新(报告编号: 202336000Z08X404), 该产品是全球首款经股动脉弓部三分支解剖性重建的全腔内主动脉支架。本文对围手术期情况给予总结, 以初步评价其应用效果与安全性。



图1 自适应三分支介入覆膜支架体外形态

Figure 1 In vitro shape of the adaptive supra-arch branched stent

1 资料与方法

1.1 一般资料

2023年10月—2023年12月, 3例主动脉弓部病变患者在中国人民解放军空军军医大学第一附属医院心血管外科接受新型自适应三分支介入覆膜支架系统治疗。入选患者均由主动脉计算机体层成像血管造影(computed tomography angiography, CTA)明确诊断为主动脉弓部病变, 其中1例为主动脉弓部夹层动脉瘤, 2例为主动脉弓部瘤伴溃疡。满足以下标准的患者被纳入研究: (1) 年满18~80岁; (2) 需重建无名动脉或/和左颈总动脉或/和左锁骨下动脉; (3) 解剖学标准: 升主动脉长度 ≥ 60 mm(从主动脉窦冠交界处到无名动脉近心段), 升主动脉直径 $\geq 26\sim 42$ mm; 升主动脉锚定区长度 ≥ 30 mm, 近端破口距窦冠交界 ≥ 30 mm; 无名动脉长度 ≥ 20 mm, 无名动脉直径10~22 mm; 左颈总动脉或左锁骨下动脉长度 ≥ 20 mm, 左颈总动脉或左锁骨下动脉直径7~13 mm; (4) 具有合适的股动脉、髂动脉入路可行主动脉腔内治疗。排除标准: (1) 同一次手术需要干预其他血管病变; (2) 有主动脉弓部外科手术或腔内修复手术治疗史; (3) 覆膜支架锚定区域存在严重狭窄或者钙化或者扭曲、血栓, 容易导致覆膜支架贴壁不良; (4) 严重肝/肾功能衰竭、凝血功能障碍的患者; (5) 妊娠期或哺乳期女性; (6) 已知对造影剂、覆膜支架及输送器材料过敏; (7) 术前3个月内有急性心肌梗死、脑梗或脑出血病史; (8) 预期寿命 < 12 个月(如恶性肿瘤晚期)。该研究在患者及家属知情同意下完成, 并得到中国人民解放军空军军医大学第一附属医院医学伦理审查委员会批准(许可证号: KY20232010-F-1)。

1.2 手术方法

3例患者均在全麻及全身肝素化下接受手术治疗, 双侧股动脉穿刺并放置鞘管, 全身肝素化(1 mg/kg)。穿刺左侧颈动脉并放置鞘管, 正位透视下, 经颈动脉鞘管送入5 F黄金标记猪尾导管至升主动脉腔内; 经右侧股动脉鞘管送入6 F猪尾导管至升主动脉, 左前斜45°位, 行数字减影血管造

影 (digital subtraction angiography, DSA) 检查, 了解主动脉弓部病变及三分支血管情况; 经右侧股动脉沿加硬导丝将自适应三分支介入覆膜支架主体系统经股动脉-腹主动脉-胸主动脉-主动脉弓至升主动脉; 调整主动脉支架位置, 使覆膜支架起始部位位于预先设计的主动脉锚定区, 并使支架左颈总口对准左侧颈总动脉开口位置; 释放支架。

撤出输送系统, 将可调弯管自右侧股动脉鞘管内置入, 导丝引导下从主支架第二孔穿出, 送入左颈总动脉内, 交换加硬导丝, 沿导丝送入左颈总动脉分支支架近端位于主支架近端开口位置, 远端位于左颈总动脉内, 释放支架; 撤出输送系统将可调弯管自右侧股动脉鞘管内置入, 导丝引导下从主支架第一孔穿出, 送入无名动脉内, 交换加硬导丝, 沿导丝送入无名动脉分支支架, 近端位于主支架近端开口位置, 远端位于无名动脉, 释放支架; 再次撤出输送系统, 将可调弯导管自右侧股动脉鞘管内置入, 导丝引导下从主支架第三孔穿出, 送入左锁骨下动脉内, 交换加硬导丝, 沿导丝送入左锁骨下动脉分支支架, 近端位于主支架近端开口位置, 远端位于左锁骨下动脉, 释放支架。撤出输送系统, 沿加硬导丝将主动脉

覆膜支架延长段放置于前支架远端, 两支架重叠3节以上情况下, 根据降主动脉形态选择支架远端锚定位置, 释放支架; 完成弓部重建及主动脉塑形。

1.3 术后处理及随访

术后常规抗凝处理6个月。患者需按指定时间(术后3 d、1、3、6、12个月)完成主动脉CTA随访, 观察支架有无移位、断裂及形态有无变化, 主动脉及分支动脉血流是否通畅, 有无内漏等不良事件发生。定期整体评估患者状况, 有无心脑血管事件等并发症的发生。

2 结果

2.1 基线特征

本研究3例病例均为男性, 年龄50~74岁; 体质量65~85 kg。3例患者均合并高血压, 1例合并糖尿病。患者主观症状情况: 急性胸部疼痛1例, 胸背部隐痛1例, 无症状体检发现1例。术前病变特点: 主动脉弓部溃疡2例; 主动脉弓部瘤伴夹层1例; 其中瘤体累及左颈总动脉1例; 3例病变均累及至主动脉1区, 其中1例病变累及至主动脉0区(表1)。

表1 患者基本信息及术前病变特点

Table 1 The general data and preoperative lesion characteristics of the patients

序号	年龄(岁)	体质量(kg)	症状	合并症	病变范围	病变类型	是否累及分支血管
第1例	50	65	急性胸痛	高血压	0~3区	主动脉弓部瘤伴夹层	累及左颈总、无名动脉
第2例	74	70	胸痛	高血压、糖尿病	1~3区	主动脉弓部溃疡	累及左颈总动脉
第3例	53	85	无症状	高血压	1~3区	主动脉弓部溃疡	累及左颈总动脉

2.2 患者手术相关情况

3例患者术中支架均顺利植入, 平均手术时间125 min。第1例患者带管入重症监护室(ICU),

其余2例均于手术室内拔管, 平均ICU停留时间31 h。围手术期无心脑血管事件等并发症出现, 3例患者均在术后5 d内康复出院(表2)。

表2 患者手术相关情况

Table 2 Surgical-related information of the patients

序号	手术时间(min)	术中带管时间(min)	ICU停留时间(h)	术后住院时间(d)
第1例	180	未拔管	46	4
第2例	80	198	23	4
第3例	115	135	23	4

无新发血管破裂、急性心脑血管事件等并发症。所有支架均经股动脉路入导入。术中主动脉主体支架释放后窗口与分支血管开口对位精准, 无弓部分支血流阻闭期。术中弓部三分支血管超

选顺利, 分支支架植入顺利。术中DSA提示: 支架位置良好, 无移位; 分支血管血流通畅, 无狭窄; 病变完全隔绝, 无内漏(图2)。

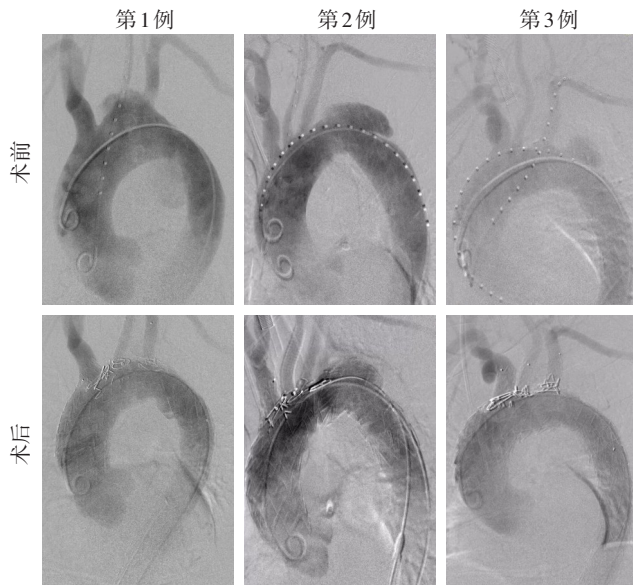


图2 手术前后DSA图像

Figure 2 Preoperative and postoperative CTA images

3例患者均完成术后1个月随访。患者术后恢复良好，无不适主诉。3例患者术后复查主动脉CTA均显示主体支架及分支支架位置、形态良好，弓部三支血管血流通畅，病变瘤体隔绝良好，无内漏（图3）。

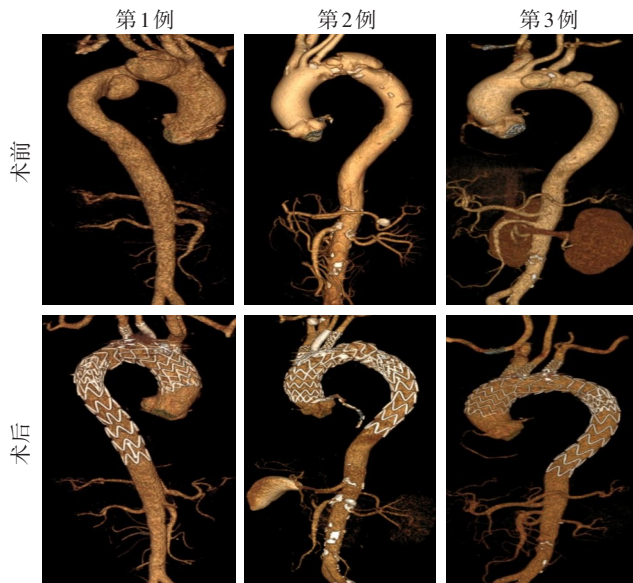


图3 手术前后CTA图像

Figure 3 The preoperative and postoperative CTA images

3 讨论

主动脉弓部病变腔内治疗既要保证治疗效果，又要最大限度减少创伤。但目前各种弓部病变腔内技术仍存在需要突破的问题：(1) 弓部分支供血

问题，目前临床应用的体内开窗技术主动脉支架释放后，存在一段时间弓部分支血流阻闭^[11]，而体外开窗时则存在窗口对位不准同样影响弓部分支血供^[12]；(2) 内漏问题^[13]，体外开窗存在窗口过大及对位不准时多出现内漏^[14]，平行支架应用病例中内漏发生率也较高^[15]；(3) 颈部创伤问题，目前弓部腔内技术多数需在颈部建立多个穿刺通路^[16]，甚至需要切开行颈部动脉搭桥术^[17]，创伤较大，脑梗等不良事件发生率高^[18]。如何同时完美解决上述难题，是本研究中初次应用新型支架需面对的极大挑战。

通过3例病例的临床应用经验，笔者总结该支架以下三点优势：(1) 支架系统均由股动脉导入，进一步减小创伤。目前弓部腔内技术多数需在颈部建立多个穿刺通路^[19]，而且还需要切开颈动脉作为颈部血管分支重建的通路，有的技术甚至需要切开行颈部动脉搭桥术^[20-21]。不仅创伤仍较大，而且在侵扰多根颈部动脉的状态下，脑梗等不良事件发生率会显著增加。本研究所使用的支架系统在植入过程中只需穿刺左颈总动脉建立一条通路，且该颈部通路仅用于定位及造影，不导入过粗鞘管，将颈部创伤降到最低。所有支架系统均通过股动脉入路导入，且建立股动脉通路时，仅需腔内缝合器就可完成血管闭合任务，无需行外科切口建立动脉通道。因此，最大限度地降低了创伤范围，直接使手术时间明显缩短，术后恢复快。(2) 术中保证脑部持续供血，减少脑部并发症。目前临床应用的原位开窗技术主动脉主体支架释放后，存在一段时间弓部分支血流阻闭^[22]，需要配合临时性体外转流才能满足脑部供血的需求^[23]。尽管如此，接受原位开窗技术的患者中，脑缺血并发症发生率仍较高^[24]。应用体外开窗技术时，若体外预开窗口与分支动脉弓部入口对位不准，也存在脑部缺血甚至脑卒中的风险^[25]。术中脑部供血问题也是弓部血管腔内重建技术长期以来无法避免及克服的瓶颈问题^[26]。本研究3例患者术中均未经历脑部缺血的过程，手术过程顺利，术后均未出血性脑卒中等脑部并发症。(3) 解剖性矫治，内漏及分支支架闭塞等不良事件发生率低。应用体外开窗技术时，预开窗口过大往往会出现主体支架与分支支架衔接口的内漏^[27]；而对位不准则可能会导致对位口过窄，引起分支支架狭窄、闭塞等情况^[27]。应用体内开窗技术时，内漏发生可

能性有所减少,但由于术中体内窗口预扩不彻底等不良因素导致的分支支架狭窄、闭塞等情况也时有发生^[28]。平行支架技术重建弓部分支血管时,最突出的不良事件就是内漏问题^[29],并且平行支架根数越多,内漏发生率越高^[30]。本研究所使用的自适应三支介入覆膜支架凭借其主体支架独创性袖套样窗口,充分发挥支架自适应特性,保证了主体支架与分支支架的紧密衔接及血流通畅,为3例手术均获成功提供了重要解剖层面的保障,所有患者术后均未出现内漏及分支支架血流不畅等不良事件。

综上所述,自适应三支介入覆膜支架系统突破了目前临床上应用的诸多弓部腔内技术所存在的短板问题,实现了全腔内主动脉弓部解剖性重建,做到了尽量减少创伤的情况下安全地重建主动脉弓部,具有较好的临床应用前景。

利益冲突:所有作者均声明不存在利益冲突。

作者贡献声明:左健、李子林负责设计论文框架,起草论文;张静隆、李超负责实验操作,研究过程的实施;陈佳、孙子兰负责数据收集,统计学分析、绘制图表;左健负责论文修改;左健、刘金成、俞世强、易蔚负责拟定写作思路,指导撰写文章并最后定稿。

参考文献

- [1] Okada K. Total arch replacement: when and how? [J]. *Asian Cardiovasc Thorac Ann*, 2023, 31(1): 42-47. doi: 10.1177/02184923211073374.
- [2] Coselli JS, Roselli EE, Preventza O, et al. Total aortic arch replacement using a frozen elephant trunk device: results of a 1-year US multicenter trial[J]. *J Thorac Cardiovasc Surg*, 2022; S0022-S5223(22)00921-7. doi:10.1016/j.jtcvs.2022.08.029.
- [3] Beckmann E, Martens A, Kaufeld T, et al. Is total aortic arch replacement with the frozen elephant trunk procedure reasonable in elderly patients?[J]. *Eur J Cardiothorac Surg*, 2021, 60(1):131-137. doi:10.1093/ejcts/ezab063.
- [4] Song K, Kim YS, Jang WS, et al. Total arch replacement versus hybrid operation for aortic arch aneurysm in elderly patients: a retrospective cohort analysis[J]. *J Thorac Dis*, 2023, 15(8):4357-4366. doi:10.21037/jtd-23-331.
- [5] D'Onofrio A, Caraffa R, Cibin G, et al. Total endovascular aortic arch repair: from dream to reality[J]. *Medicina (Kaunas)*, 2022, 58(3):372. doi:10.3390/medicina58030372.
- [6] Bozso SJ, White A, Nagendran J, et al. Hybrid aortic arch and frozen elephant trunk reconstruction: bridging the gap between conventional and total endovascular arch repair[J]. *Expert Rev Cardiovasc Ther*, 2018, 16(3): 209-217. doi: 10.1080/14779072.2018.1429913.
- [7] Xiang Y, Qiu C, He Y, et al. A single center experience of in situ needle fenestration of supra-aortic branches during thoracic endovascular aortic repair[J]. *Ann Vasc Surg*, 2019, 61:107-115. doi:10.1016/j.avsg.2019.03.016.
- [8] Wang M, Dong D, Yuan H, et al. Hybrid versus in vitro fenestration for preserving the left subclavian artery in patients undergoing thoracic endovascular aortic repair with unfavorable proximal landing zone[J]. *Vascular*, 2020, 28(1): 42-47. doi: 10.1177/1708538119862952.
- [9] Wang W, Zhang X, Liu C, et al. A novel internal and external bypass method to safeguard cerebral blood flow during aortic arch endovascular repair requiring triple in situ fenestrations[J]. *J Endovasc Ther*, 2019, 26(5): 652-657. doi: 10.1177/1526602819865503.
- [10] 舒畅,何昊,李全明,等.新型一体三支支架系统用于主动脉弓部病变的FIM研究[J].*中国普通外科杂志*, 2023, 32(6):824-831. doi:10.7659/j.issn.1005-6947.2023.06.003.
Shu C, He H, Li QM, et al. First-in-man study of a novel integrated supra-arch branched stentgraft system for aortic arch lesions[J]. *China Journal of General Surgery*, 2023, 32(6): 824-831. doi: 10.7659/j.issn.1005-6947.2023.06.003.
- [11] Shehab M, Mani K, Kuzniar M, et al. Urgent endovascular mycotic aortic arch aneurysm repair using in situ laser fenestration and selective arterial perfusion with venoarterial extracorporeal membrane oxygenation[J]. *J Vasc Surg Cases Innov Tech*, 2023, 9(4):101345. doi:10.1016/j.jvscit.2023.101345.
- [12] Joseph G, Thomson VS, Thankachen R, et al. A system for accurate deployment of unconstrained triple-fenestrated aortic arch endografts[J]. *J Endovasc Ther*, 2022, 29(6):893-903. doi:10.1177/15266028211067737.
- [13] Kudo T, Kuratani T, Shirakawa Y, et al. Comparison of the outcomes of total endovascular aortic arch repair between branched endograft and chimney endograft technique in zone 0 landing[J]. *J Endovasc Ther*, 2022, 29(3): 427-437. doi: 10.1177/15266028211059912.
- [14] Yuri K, Kimura N, Hori D, et al. A challenging treatment for aortic arch aneurysm with fenestrated stent graft[J]. *Ann Thorac Surg*, 2017, 104(6):1915-1922. doi:10.1016/j.athoracsur.2017.05.062.
- [15] Liu M, Wu X, Wu S, et al. Comparison of chimney and fenestrated techniques for supra-aortic branch revascularization during thoracic endovascular aortic repair: a systematic review and meta-

- analysis[J]. *Cardiovasc Intervent Radiol*, 2023, 46(10): 1315–1328. doi:10.1007/s00270-023-03537-4.
- [16] van Bakel TM, de Beaufort HW, Trimarchi S, et al. Status of branched endovascular aortic arch repair[J]. *Ann Cardiothorac Surg*, 2018, 7(3):406–413. doi:10.21037/acs.2018.03.13.
- [17] Rong D, Zhang H, Guo W, et al. Preclinical evaluation of a non-customized modular inner branched stent graft for total endovascular aortic arch repair in a porcine model[J]. *J Endovasc Ther*, 2023, 30(4):628–636. doi:10.1177/15266028221090445.
- [18] Tazaki J, Inoue K, Higami H, et al. Thoracic endovascular aortic repair with branched Inoue Stent Graft for arch aortic aneurysms[J]. *J Vasc Surg*, 2017, 66(5):1340–1348.e5. doi:10.1016/j.jvs.2017.03.432.
- [19] Singh S, Surkhi AO, Tan SZCP, et al. RELAY TM branched-international results of vessel patency and reintervention[J]. *Front Cardiovasc Med*, 2022, 9:962884. doi:10.3389/fcvm.2022.962884.
- [20] Zhu Y, Li F, Zhang H, et al. Hemodynamic numerical simulation of aortic arch modular inner branched stent-graft in eight early patients from the first-in-human case series[J]. *Front Cardiovasc Med*, 2022, 9:981546. doi:10.3389/fcvm.2022.981546.
- [21] Vendramin I, Lechiancole A, Frigatti P, et al. Aortic arch aneurysm and Kommerell's diverticulum: repair with a single-stage hybrid approach[J]. *J Card Surg*, 2019, 34(7): 641–644. doi: 10.1111/jocs.14099.
- [22] Grima MJ, Wanhainen A, Lindström D. In situ laser fenestration technique: bench-testing of aortic endograft to guide clinical practice[J]. *J Endovasc Ther*, 2024, 31(1): 126–131. doi: 10.1177/15266028221119315.
- [23] Zeng QL, Zhou X, He YJ, et al. Experimental analysis of in situ fenestration of endovascular stent-grafts: comparison between needle and laser puncture[J]. *Ann Vasc Surg*, 2021, 77: 280–287. doi:10.1016/j.avsg.2021.05.021.
- [24] Boufi M, Alexandru G, Tarzi M, et al. Systematic review and meta-analysis of ex-situ and In-situ fenestrated stent-grafts for endovascular repair of aortic arch pathologies[J]. *J Endovasc Ther*, 2023:15266028231157639. doi:10.1177/15266028231157639.
- [25] Georgiadis GS, van Herwaarden JA, Antoniou GA, et al. Systematic review of off-the-shelf or physician-modified fenestrated and branched endografts[J]. *J Endovasc Ther*, 2016, 23(1):98–109. doi:10.1177/1526602815611887.
- [26] Hill MA, Wooster M, Zeigler S. Palliative repair of a mycotic aortic arch pseudoaneurysm with a physician-modified endograft and In-situ laser fenestration[J]. *J Endovasc Ther*, 2024, 31(1): 132–135. doi:10.1177/15266028221107879.
- [27] Brinster CJ, Milner R. Fenestrated endovascular aortic repair and clinical trial devices for complex abdominal aortic aneurysms[J]. *J Cardiovasc Surg*, 2018, 59(3): 342–359. doi: 10.23736/S0021-9509.18.10460-5.
- [28] Eudailey KW, von Mering G, Johanson P, et al. Total endovascular arch repair using needle fenestration and extracorporeal membrane oxygenation[J]. *Ann Thorac Surg*, 2020, 109(2): e127–e129. doi: 10.1016/j.athoracsur.2019.05.064.
- [29] Schenning RC, Al-Hakim R. Aortic dissection: branched, fenestrated, and parallel aortic stent grafts in the ascending aorta and arch[J]. *Tech Vasc Interv Radiol*, 2021, 24(2): 100754. doi: 10.1016/j.tvir.2021.100754.
- [30] Li Y, Hu ZZ, Wang JC, et al. Endovascular chimney technique for aortic arch pathologies treatment: a systematic review and meta-analysis[J]. *Ann Vasc Surg*, 2018, 47: 305–315. doi: 10.1016/j.avsg.2017.09.006.

(本文编辑 宋涛)

本文引用格式:左健,刘金成,俞世强,等.新型全腔内经股动脉三分支覆膜支架系统治疗主动脉弓部病变的FIM研究[J].中国普通外科杂志,2024,33(6):894–900. doi: 10.7659/j.issn.1005-6947.2024.06.004

Cite this article as: Zuo J, Liu JC, Yu SQ, et al. First-in-man study of a new femoral endovascular access supra-arch branched stent graft for the treatment of aortic arch disease[J]. *Chin J Gen Surg*, 2024, 33(6): 894–900. doi:10.7659/j.issn.1005-6947.2024.06.004