



doi:10.7659/j.issn.1005-6947.2021.06.008  
http://dx.doi.org/10.7659/j.issn.1005-6947.2021.06.008  
Chinese Journal of General Surgery, 2021, 30(6):686-692.

· 临床研究 ·

## 腹主动脉瘤腔内治疗术后主髂动脉破裂的治疗

王瞰<sup>1,2</sup>, 舒畅<sup>1,2,3,4</sup>, 李全明<sup>1,2</sup>, 何昊<sup>1,2</sup>, 黎明<sup>1,2</sup>, 李鑫<sup>1,2</sup>, 罗明尧<sup>3,4</sup>, 方坤<sup>3,4</sup>, 史静铮<sup>5</sup>

(1. 中南大学湘雅二医院 血管外科, 湖南 长沙 410011; 2. 中南大学血管病研究所, 湖南 长沙 410011; 3. 中国医学科学院阜外医院 血管外科, 北京 100037; 4. 国家心血管病中心, 北京 100037; 5. 中南大学湘雅公共卫生学院 流行病学与卫生统计学系, 湖南 长沙 410078)

### 摘要

**背景与目的:** 腹主动脉瘤(AAA)腔内治疗术(EVAR)的发展和推广使患者的寿命显著延长, 也伴随越来越多的术后远期并发症发生, 其中最严重的就是术后主髂动脉继续扩张最终破裂, 病情凶险、治疗难度大。本文通过回顾性分析本中心收治的EVAR术后主髂动脉破裂的病例, 探讨、总结该疾病的治疗策略。

**方法:** 回顾性分析2016年6月—2020年8月手术治疗AAA行EVAR术后主髂动脉破裂患者21例患者资料, 其中, 男性18(85.7%)例; 主动脉和髂动脉发生破裂时最大直径分别为(111.1±13.1)mm和(100.4±6.6)mm; 破裂平均发生在术后(62.0±21.2)个月; 导致瘤体破裂的原因包括: I型内漏15例(71.4%), II型内漏4例(19.0%), 不明原因内漏2例(9.5%)。

**结果:** 5例(23.8%)行急诊手术, 10例(47.6%)采用腔内手术, 11例(52.4%)患者采用“主动脉球囊阻断联合主髂动脉缩缝”的开放手术。腔内手术和开放手术的平均手术时间分别为(68.1±12.0)min和(236.4±48.6)min。围手术期死亡1例(4.8%), 开放手术重症监护时间1~3d。平均随访时间(21.3±17.7)个月, 2例(2/9, 22.2%)腔内手术患者因腹主动脉病变再次接受手术治疗。

**结论:** 主髂动脉破裂是一种严重的EVAR术后远期并发症。内漏, 尤其I型, 是导致其发生的主要原因。腔内手术是首选治疗策略, “主动脉球囊阻断联合缩缝技术”的开放手术具有较好的安全性和有效性。

### 关键词

主动脉瘤, 腹; 动脉瘤, 破裂; 血管内操作

中图分类号: R654.3

## Surgical treatment of late rupture of abdominal aortic/iliac artery aneurysm after previous endovascular repair

WANG Tun<sup>1,2</sup>, SHU Chang<sup>1,2,3,4</sup>, LI Quanming<sup>1,2</sup>, HE Hao<sup>1,2</sup>, LI Ming<sup>1,2</sup>, LI Xin<sup>1,2</sup>, LUO Mingyao<sup>3,4</sup>, FANG Kun<sup>3,4</sup>, SHI Jingzheng<sup>5</sup>

(1. Department of Vascular Surgery, the Second Xiangya Hospital, Central South University, Changsha 410011, China; 2. Institute of Vascular Disease, Central South University, Changsha 410011, China; 3. Department of Vascular Surgery, Fuwai Hospital, Academy of Medical Sciences, Beijing 100037, China; 4. National Center for Cardiovascular Disease, Beijing 100037, China; 5. Department of Epidemiology and Health Statistics, Xiangya School of Public Health, Central South University, Changsha 410078, China)

### Abstract

**Background and Aims:** The development and promotion of endovascular aortic repair (EVAR) for abdominal aortic aneurysm (AAA) have significant prolonged the survival of patients, but also accompanied by an increasing

收稿日期: 2021-03-29; 修订日期: 2021-05-25。

作者简介: 王瞰, 中南大学湘雅二医院医院主治医师, 主要从事血管外科方面的研究。

通信作者: 舒畅, Email: changshu\_vascular@163.com

incidence of long-term complications, and among them, the most serious one is postoperative dilation and eventual rupture of the aortic/iliac artery, which is highly severe and difficult to treat. This study was conducted to investigate and summarize the treatment strategies for this condition through retrospective analysis of cases with late rupture of the abdominal aortic/iliac artery aneurysm after previous EVAR treated in our center.

**Methods:** The clinical data of 21 patients with late rupture of the abdominal aortic/iliac artery aneurysm after EVAR for AAA undergoing surgical treatment from June 2016 to August 2020 were retrospectively analyzed. Of the patients, 18 cases (85.7%) were males; the maximal diameter of aortic and iliac artery were (111.1±13.1) mm and (100.4±6.6) mm; the duration from EVAR to aortic rupture was (62.0±21.2) months; the reasons including type I endoleak in 15 cases (71.4%), type II endoleak in 4 cases (19.0%) and unclear endoleak in 2 cases (9.5%).

**Results:** Five patients (23.8%) received emergency operation, 10 patients (47.6%) underwent endovascular procedure and 11 patients (52.4%) were subjected to open surgery of balloon occlusion of the balloon plus coarctation suture of the aortic/iliac artery. The average operative time for endovascular and open surgery were (68.1±12.0) min and (236.4±48.6) min. Perioperative death occurred in one patient (4.8%). The length of intensive care unit stay after open surgery was 1–3 d. The mean follow-up period was (21.3±17.7) months, and 2 patients (2/9, 22.2%) undergoing endovascular treatment received secondary operation for abdominal aortic complications.

**Conclusion:** Late rupture of abdominal aortic/iliac artery aneurysm is a severe long-term complication after EVAR. Endoleak, especially the type I endoleak, is the main cause for this condition. Endovascular aortic repair is the first treatment option. The open surgery of balloon occlusion of the balloon plus coarctation suture of the aortic/iliac artery is relatively safe and effective.

#### Key words

Aortic Aneurysm, Abdominal; Aneurysm, Ruptured; Endovascular Procedures; open surgery

CLC number: R654.3

腹主动脉瘤 (abdominal aortic aneurysm, AAA) 是一种老年常见的严重主动脉疾病<sup>[1-2]</sup>。腹主动脉覆膜支架腔内修复治疗 (endovascular aortic repair, EVAR) 始于上世纪90年代, 具有创伤小、并发症少、病死率低等优点, 经过30年的发展, 已经基本取代开放手术, 成为AAA首选的手术治疗策略<sup>[2-5]</sup>。然而, 随着EVAR手术的大量普及和患者预期生命的延长, 近年EVAR术后远期并发症逐渐显现, 呈逐年增高趋势, 尤其是EVAR术后远期主髂动脉仍继续扩张最终破裂, 致病机制复杂多样, 病情凶险, 致死率高, 治疗难度大, 受到国内外学者广泛关注, 成为目前EVAR临床研究的焦点问题<sup>[4, 6, 8-13]</sup>。

EVAR术后主髂动脉破裂的治疗, 由于缺少大样本临床研究的总结报道, 目前尚无统一的临床治疗指导方案。我中心开展了大量AAA的EVAR手术治疗, 具有丰富的临床诊治经验。本文回顾性研究中心2016—2020年收治的21例EVAR术后主髂动脉破裂的病例, 探讨、总结该疾病的治疗策略。

## 1 资料与方法

### 1.1 研究对象

回顾性研究2016年6月—2020年8月, 血管外科中心共手术治疗EVAR术后主髂动脉破裂的患者21例, 患者相关临床资料见表1。EVAR术后主髂动脉破裂的临床诊断包括: (1) 增强CT典型的主髂动脉破裂表现和临床表现; (2) 增强CT有疑似破裂表现, 如: 存在内漏并瘤体边界不清, 同时瘤体较EVAR术前显著增加, 通常最大直径>80 mm, 同时合并排除其他原因的腹痛, 出现血压降低、心率增快等血流动力学改变, 要高度怀疑主髂动脉破裂。

### 1.2 治疗方式

所有患者入院后均尽快完成全主动脉增强CT检查和手术前准备工作, 并予以积极的保守治疗, 包括: 要求患者卧床休息, 并监测生命体征; 高血压患者予以适当降压, 将收缩压控制在约130 mmHg (1 mmHg=0.133 kPa); 病因明确的腹痛予以对症治疗; 出现失血导致的血流动力学改变患者予以积极补液等预防休克治疗, 并尽快实施手术。

根据患者的病变解剖学条件和患者的手术耐受能力制定手术治疗策略,包括:(1)针对Ia型内漏。当肾动脉以下存在 $\geq 0.5$  cm的锚定区,采用平肾动脉下沿植入主动脉Cuff支架;当肾动脉以下锚定区 $< 0.5$  cm,采用平肠系膜上动脉下沿植入Cuff支架联合双侧肾动脉烟囱支架技术;当肾动脉以下锚定区 $< 0.5$  cm,但Ia内漏的轴向位置距离肾动脉开口 $> 0.5$  cm,采用双肾动脉开窗Cuff技术,平肠系膜上动脉下沿植入Cuff支架。(2)针对Ib型内漏。采用弹簧圈封堵同侧髂内动脉,再植入髂动脉延长支架,封堵髂总动脉、髂内动脉开口和髂外动脉起始端。(3)针对肠系膜下动脉II型内漏。采用肠系膜上动脉入路,进入肠系膜下动脉起始段的弹簧圈封堵技术。(4)针对不明原因的、反复发作的、无法采用腔内技术治疗的内漏,和髂内动脉弹簧圈栓塞后依然返血导致的主髂动脉破裂,采用“主动脉球囊阻断联合主动脉缩缝”手术治疗。首先通过肱动脉入路在DSA引导下将主动脉顺应性球囊置入降主动脉远心端阻断;采用自体血回输;纵行剖开主髂动脉瘤腔,清除其内血栓,缝扎腰动脉、肠系膜下动脉和髂内动脉,修剪多余部分瘤壁,将修剪后的瘤壁紧贴EVAR支架,紧密缩缝。

表1 研究对象的临床资料

Table 1 Clinical data of the studied patients

项目	数据
年龄 [岁, $\bar{x} \pm s$ (范围)]	65.4 $\pm$ 11.4 (56~77)
性别 [n (%)]	
男	18 (85.7)
女	3 (14.3)
临床表现 [n (%)]	
腹痛	21 (100.0)
血流动力学改变	5 (23.8)
术后破裂发生平均时间 [月, $\bar{x} \pm s$ (范围)]	62.0 $\pm$ 21.2 (17~97)
发生破裂时动脉直径 [mm, $\bar{x} \pm s$ (范围)]	
主动脉	111.1 $\pm$ 13.1 (88~138)
髂动脉	100.4 $\pm$ 6.6 (99~109)
导致破裂的原因 [n (%)]	
I型内漏	15 (71.4)
Ia型内漏	10 (47.6)
Ib型内漏	4 (19.0)
Ia合并Ib内漏	1 (4.8)
II型内漏	4 (19.0)
肠系膜下动脉II型内漏	1 (4.8)
髂内动脉栓塞后依然返血	3 (14.3)
不明原因内漏	2 (9.5)

### 1.3 随访方式

患者术后2周扫描主髂动脉CTA,检查瘤体破

裂封堵情况,包括内漏、腹膜后血肿等。术后3、6个月和以后每年进行随访,复查全主髂动脉CTA。

## 2 结果

### 2.1 手术结果

手术成功率100%,无术中死亡病例。5例(23.8%,3例腔内,2例开放)采取急诊手术。10例(47.6%)采用腔内手术治疗,其中4例植入Cuff支架(图1),1例采用双烟囱重建双侧肾动脉,1例植入双开窗Cuff支架,4例采用弹簧圈栓塞髂内动脉联合髂动脉延长支架,1例采用弹簧圈栓塞肠系膜下动脉;腔内手术的手术时间47~87 min,平均(68.1  $\pm$  12.0) min。11例(52.4%)采用开放手术(图2),手术时间180~320 min,平均(236.4  $\pm$  48.6) min;患者均采用自体血回输,1例(9.1%)髂内动脉破裂患者额外输注4单位红细胞。

### 2.2 围手术期结果

1例(4.8%)患者发生围手术期死亡。该患者术前出现血流动力学改变,采取急诊腔内手术治疗;术中采用弹簧圈栓塞双侧髂内动脉,并将双侧髂动脉支架延长至髂外动脉起始段,封堵髂内动脉开口,未见明显内漏;术后转入重症监护室,发生感染性休克和多器官功能衰竭死亡。其他腔内手术患者术后均回普通病房,无明显围手术期并发症。开放手术患者术后均转入重症监护室治疗,重症监护时间1~3 d,平均(1.55  $\pm$  0.8) d。

患者术后腹痛症状均缓解。术后2周CT复查,双烟囱重建双侧肾动脉患者仍存在少量Ia型内漏,余患者未见明显内漏,腹膜后血肿均基本消失。

### 2.3 随访结果

20例患者均获得随访,随访时间4~76个月,平均(21.3  $\pm$  17.7)个月。1例合并左肾严重积水,并采取开放手术治疗的,术后左侧输尿管梗阻无明显改善,术后3个月在腹腔镜下行左肾切除术。植入Cuff和双侧肾动脉烟囱支架患者,术后37个月发生右侧髂动脉支架移位导致的Ib型内漏,予以髂动脉延长支架封堵;术后76个月再发轻度腹痛,增强CT和造影DSA显示轻度Ia型内漏,瘤体最大直径维持稳定,予以保守治疗。采用弹簧圈封堵肠系膜下动脉的患者,术后21个月再发腹痛,增强CT未见明显内漏,瘤体直径无明显变化,患者要求手术治疗,予以开放手术治疗。其余患者随访期间未见明显异常。

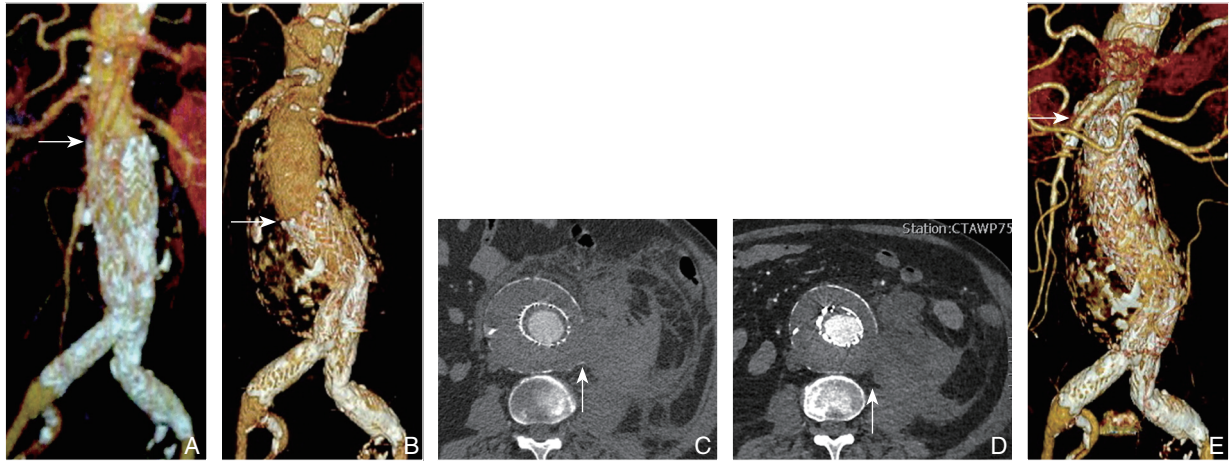


图1 腔内手术治疗Ia内漏导致的EVAR术后AAA破裂 A: EVAR术后; B: EVAR术后97个月, 支架近心端移位; C: AAA破裂位置; D-E: 腔内手术修复破裂后

Figure 1 Endovascular treatment of late rupture of AAA caused by type Ia endoleak after previous endovascular repair A: Image after EVAR; B: Transposition of the stent on 97 months after EVAR; C: the rupture site of AAA; D-E: Images after endovascular repair of the rupture

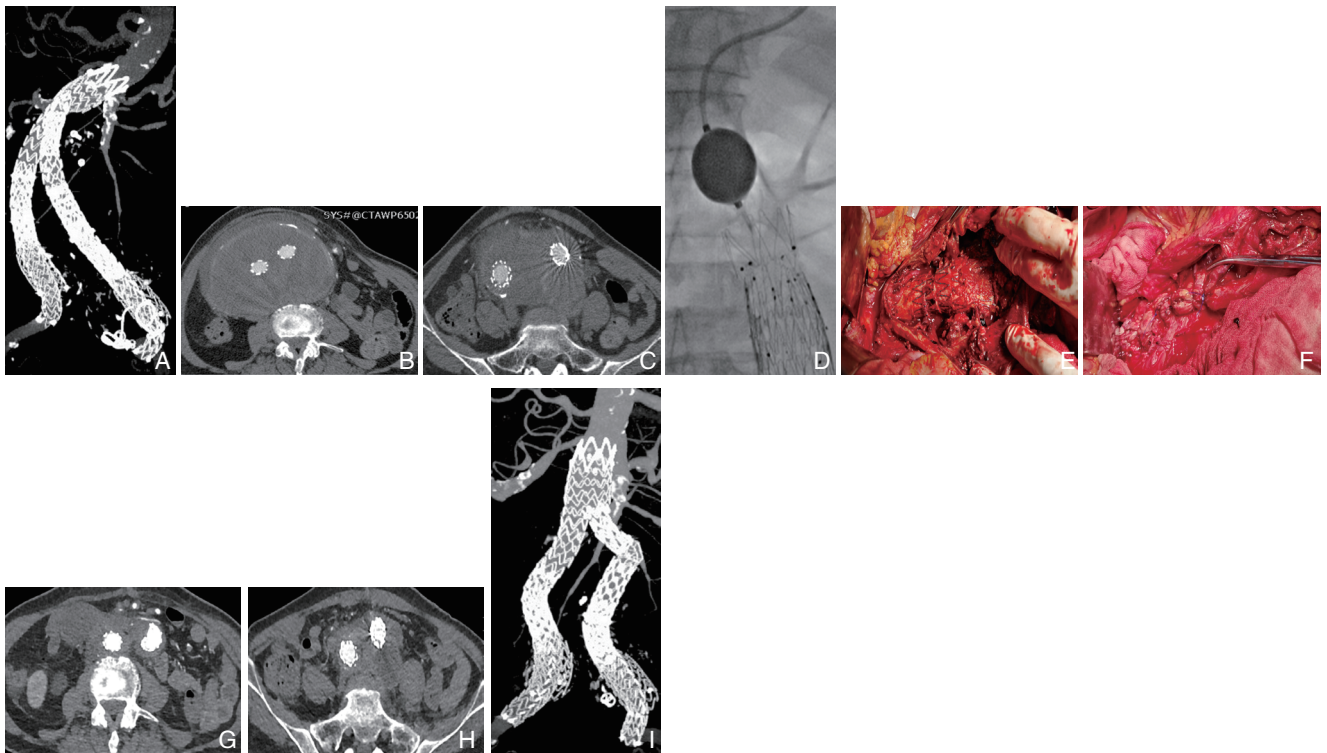


图2 开放手术治疗不明原因内漏导致的EVAR术后AAA破裂 A-C: 术前CTA, 主动脉最大直径138 mm, 局部破裂; D-F: 开放手术, 采用球囊阻断降主动脉远段(D), 无需钳夹阻断直接剖开瘤体, 缝扎分支动脉(E), 紧密缝合瘤壁于支架上(F); G-I: 术后CTA, 与术前相同平面对比, AAA已切除, 无内漏

Figure 2 Surgical treatment of late rupture of AAA caused by unclear endoleak after previous EVAR A-C: Preoperative CTA showing part rupture of the aorta with the maximum diameter of 138 mm; D-F: Open surgery using balloon occlusion of the distal part of the descending aorta (D), incision of the aneurysmal body clamp, no need of clamp, and suturing branch arteries (E), and coarctation suture of the aneurysmal wall to the stent (F); G-I: Postoperative CTA showing absence of the AAA without endoleak compared to the same plane before operation

### 3 讨论

AAA在60岁以上人群患病率达3%, 是常见的

老年严重疾病<sup>[14]</sup>。EVAR是目前AAA首选的治疗方法, 其创伤小、并发症少、术后恢复快<sup>[4, 7, 15]</sup>; 但最近研究<sup>[10-11, 13, 16]</sup>显示EVAR的远期并发症发

生率被显著低估，主要是由于术后随访率低下导致大量远期并发症被漏诊<sup>[4,17]</sup>；如在美国，EVAR术后5年随访率仅50%<sup>[17]</sup>；EVAR-1研究中，术后6年CT失访率也高达50%<sup>[4]</sup>。主髂动脉破裂就是一种EVAR术后的严重远期并发症；一般发生在术后2.4~4.9年，发生率为0.5%~11.5%，远高于之前预期<sup>[9, 11, 13, 18-19]</sup>。

内漏是导致EVAR术后主髂动脉破裂的直接原因<sup>[9,18]</sup>。本研究的所有患者均存在内漏；研究显示约80%的破裂是由内漏直接导致，其中主要是I型内漏，约占52%<sup>[18]</sup>；本研究中，90.5%的患者有明确的内漏，其中I型内漏占71.4%，是最重要的致病机制。“解剖条件复杂的AAA”和“持续存在的导致AAA的病理机制”是导致内漏的主要原因。解剖条件复杂包括瘤颈严重扭曲、瘤体直径大、合并严重髂动脉瘤等，约32%~41%的解剖条件复杂AAA术后出现瘤体仍持续扩张<sup>[9]</sup>。de Guerre等<sup>[11]</sup>研究发现，瘤体直径>6.5 cm，术后5年发生瘤体破裂的比例显著升高（11.5% vs. 6.4%），是术后破裂的独立危险因素。另外，主动脉退行性改变（degeneration）是AAA的主要发病机制<sup>[20-21]</sup>，主要包括动脉粥样硬化（约占90%）<sup>[20, 22]</sup>和血管炎性疾病（约占5%）<sup>[23-24]</sup>。EVAR不能缓解主动脉退行性改变，因而导致术后发生近远端瘤颈继续扩张、支架移位和远期I型内漏等。

EVAR术后主髂动脉破裂与破裂型AAA的临床表现有显著差异，主要是瘤体巨大和较少发生急性失血性休克。由于主动脉覆膜支架的隔绝，EVAR术后主髂动脉破裂主要发生在长期内漏导致瘤体缓慢增大的基础之上，本研究中主、髂动脉破裂时的平均最大直径分别为111.1 mm和100.4 mm，均远大于破裂型AAA的平均最大直径（58~82 mm）<sup>[25-26]</sup>。相比未行手术的AAA内的强劲主动脉血流，内漏的流量较小，即使发生破裂也能被后腹膜包裹延缓病程；因此，EVAR术后主髂动脉破裂患者通常表现为持续数天甚至更长时间的腹痛、腰痛；相比破裂型AAA，其较少发生急性血流动力学改变，术前病死率也相对较低；本研究中仅5例（23.8%）出现血流动力学改变，无失血性休克发生。

EVAR术后主髂动脉破裂的治疗目前尚无统一策略。EVAR术后主髂动脉破裂比破裂型AAA病程缓慢，因而有相对充足的手术准备时间；但其解剖条件复杂、患者年龄较大、多有较多合并

症等，治疗难度大<sup>[9, 18, 27-28]</sup>。总体认为，其围手术综合病死率约为15%~67%<sup>[18,29]</sup>，并发症发生率为50%~89%<sup>[28,30]</sup>；约1/3患者采用腔内手术后治疗，腔内手术总体病死率（12%~32%）较开放手术（28%~47%）低<sup>[18]</sup>。

腔内手术对该疾病的治疗有不可替代的意义<sup>[9,16,18]</sup>。由于一期采用EVAR手术治疗的AAA多为高龄患者，多存在高血压、糖尿病、COPD等高龄患者常见的合并症，开放手术风险较高；EVAR术后主髂动脉破裂是远期并发症，患者年龄更大，因此对这些高龄、高危患者实施开放手术风险更高；腔内手术治疗甚至是部分高危患者的唯一选择<sup>[16]</sup>。腔内手术治疗有多种方案，本研究中选择腔内治疗方案的原则是：手术能可靠、快速的封堵出血。本组患者主要采用延长近远端锚定区和弹簧圈封堵髂内动脉的方法，其方法高效、可靠。其他中心还有使用主髂动脉单边支架（aortouni-iliac stent graft）结合双侧股动脉搭桥的杂交手术，或者弹簧圈封堵I型内漏的方法<sup>[18]</sup>。笔者认为，杂交手术可靠性高，但耗时较长；弹簧圈封堵I型内漏的可靠性还有待观察。

腔内手术封堵主髂动脉破裂后，由于导致AAA的主动脉退行性改变的病因并未纠正<sup>[20]</sup>，其术后仍有发生主髂动脉破裂可能<sup>[6,18,30]</sup>。Grootes等<sup>[6]</sup>对EVAR术后瘤体直径增大有破裂风险的患者采取预防性二期腔内手术，显示再次腔内手术后，瘤体仍有持续增大风险；Candell等<sup>[30]</sup>报道15%EVAR术后主髂动脉破裂患者在最终破裂之前曾接受二期腔内手术预防破裂。本组研究中，有2例采用腔内手术治疗的患者，术后随访依然存在主髂动脉破裂风险，其中1例再次行开放手术治疗。因此，腔内手术治疗后密切的随访观察仍然非常重要。

内漏或主髂动脉破裂无法通过腔内治疗封堵、腔内术后仍然反复发生内漏或内漏难以明确来源，开放手术成为被迫选择。研究报道有约45%~60%的患者采取开放手术治疗<sup>[16, 18]</sup>。学术界目前没有能够获得广泛认可的开放手术治疗方案<sup>[9, 16, 23, 30]</sup>；由于开放手术、麻醉等对高龄和/或存在严重合并症的患者有很高风险，手术方案的选择应该方法可靠；步骤精简，缩短手术时长；减少出血。因此，复杂的传统胸腹联合手术取出支架后再行人工血管置换的手术方案显然不是理想的选择。笔者首次提出“主动脉球囊阻断联合

主髂动脉缩缝”的治疗策略,其大量优化了传统手术步骤,具有显著优势。首先,相比传统手术中的“解剖、分离AAA近端瘤颈并钳夹阻断”,“球囊阻断法”有同样可靠的阻断效果,而且操作非常迅速,能显著缩短手术时长、减少主动脉破裂出血。第二,相比传统手术的“人工血管置换”,“主髂动脉缩缝”将主动脉壁紧密缝合在人工血管上,简化了人工血管置换的步骤,进一步缩短了手术时间,同时避免了吻合口出血等相关手术风险。本组11例患者通过开放手术获得理想的预后,无手术相关并发症发生。

综上所述,EVAR术后主髂动脉破裂是一种严重的EVAR术后远期并发症。内漏是导致其发生的主要原因,尤其是Ia型内漏。其较破裂型AAA瘤体直径更大,但较少发生严重的血流动力学改变。需要根据病变的解剖学和相关疾病制定个体化的腔内手术或开放手术方案,腔内手术是首选的手术方案。“主动脉球囊阻断联合缩缝技术”的开放手术方案具有较好的安全性和有效性。

#### 参考文献

- [1] Chan WK, Yong E, Hong Q, et al. Systematic review and meta-analysis of the prevalence of abdominal aortic aneurysm in Asian populations[J]. *J Vasc Surg*, 2021,73(3):1069–1074.e1.
- [2] 王磊,潘柏宏,杨璞,等.美国血管外科学会2018年腹主动脉瘤诊治指南解读[J].*中国普通外科杂志*,2018,27(12):1505–1510. doi:10.7659/j.issn.1005–6947.2018.12.002.  
Wang L, Pan BH, Yang P, et al. Interpretation of the Society for Vascular Surgery practice guidelines on the care of patients with an abdominal aortic aneurysm[J]. *Chinese Journal of General Surgery*, 2018, 27(12):1505–1510. doi:10.7659/j.issn.1005–6947.2018.12.002.
- [3] United Kingdom EVAR Trial Investigators, Greenhalgh RM, Brown LC, et al. Endovascular versus open repair of abdominal aortic aneurysm[J]. *N Engl J Med*, 2010, 362(20):1863–1871. doi:10.1056/NEJMoa0909305.
- [4] Patel R, Sweeting MJ, Powell JT, et al. Endovascular versus open repair of abdominal aortic aneurysm in 15-years' follow-up of the UK endovascular aneurysm repair trial 1 (EVAR trial 1): a randomised controlled trial[J]. *Lancet*, 2016, 388(10058):2366–2374. doi:10.1016/S0140–6736(16)31135–7.
- [5] Powell JT, Wanhainen A. Analysis of the Differences Between the ESVS 2019 and NICE 2020 Guidelines for Abdominal Aortic Aneurysm[J]. *Eur J Vasc Endovasc Surg*, 2020, 60(1):7–15. doi:10.1016/j.ejvs.2020.04.038.
- [6] Grootes I, Barrett JK, Ulug P, et al. Predicting risk of rupture and rupture-preventing reinterventions following endovascular abdominal aortic aneurysm repair[J]. *Br J Surg*, 2018, 105(10):1294–1304. doi:10.1002/bjs.10964.
- [7] 郭伟,贺元.复杂腹主动脉瘤对近端锚定区的要求及不同技术的评价[J].*中国普通外科杂志*,2020,29(6):645–648. doi:10.7659/j.issn.1005–6947.2020.06.001.  
Guo W, He Y. Proximal landing zone requirements in complex abdominal aortic aneurysms and evaluation of different techniques[J]. *Chinese Journal of General Surgery*, 2020, 29(6):645–648. doi:10.7659/j.issn.1005–6947.2020.06.001.
- [8] Wanken ZJ, Barnes JA, Trooboff SW, et al. A systematic review and meta-analysis of long-term reintervention after endovascular abdominal aortic aneurysm repair[J]. *J Vasc Surg*, 2020, 72(3):1122–1131. doi:10.1016/j.jvs.2020.02.030.
- [9] Rajendran S, May J. Late rupture of abdominal aortic aneurysm after endovascular repair[J]. *J Vasc Surg*, 2017, 65(1):52–57. doi:10.1016/j.jvs.2016.05.090.
- [10] Väärämäki S, Salenius J, Pimenoff G, et al. Overall outcome after endovascular aneurysm repair with a first-generation stent graft (Vanguard): A 20-year single-center experience[J]. *J Vasc Surg*, 2020, 72(3):896–903. doi:10.1016/j.jvs.2019.11.027.
- [11] de Guerre LEVM, Dansey K, Li C, et al. Late outcomes after endovascular and open repair of large abdominal aortic aneurysms[J]. *J Vasc Surg*, 2021, S0741–5214(21)00326–8. doi:10.1016/j.jvs.2021.02.024. [Online ahead of print]
- [12] Dubois L, Harlock J, Gill HL, et al. A Canadian multicenter experience describing outcomes after endovascular abdominal aortic aneurysm repair stent graft explantation[J]. *J Vasc Surg*, 2021, S0741–5214(21)00193–2. doi:10.1016/j.jvs.2021.01.049. [Online ahead of print]
- [13] Andersson M, Talvitie M, Benson L, et al. A Population Based Study of Post-EVAR Rupture during 15 years[J]. *J Vasc Surg*, 2021, S0741–5214(21)00233–0. doi:10.1016/j.jvs.2021.01.065. [Online ahead of print]
- [14] Duftner C, Seiler R, DeJaco C, et al. Antiphospholipid antibodies predict progression of abdominal aortic aneurysms[J]. *PLoS One*, 2014, 9(6):e99302. doi:10.1371/journal.pone.0099302.
- [15] 兰勇,王征,李大军,等.主动脉EVAR治疗腹主动脉瘤的临床效果分析[J].*中国普通外科杂志*,2017,26(12):1628–1632. doi:10.3978/j.issn.1005–6947.2017.12.019.  
Lan Y, Wang Z, Li DJ, et al. Analysis of clinical efficacy of aortic EVAR treatment of abdominal aortic aneurysm[J]. *Chinese Journal of General Surgery*, 2017, 26(12):1628–1632. doi:10.3978/

- j.issn.1005-6947.2017.12.019.
- [16] Geraedts ACM, Mulay S, Vahl A, et al. Secondary Interventions and Long-term Follow-up after Endovascular Abdominal Aortic Aneurysm Repair[J]. *Ann Vasc Surg*, 2021, 71:381-391. doi: 10.1016/j.avsg.2020.07.042.
- [17] Schanzer A, Messina LM, Ghosh K, et al. Follow-up compliance after endovascular abdominal aortic aneurysm repair in Medicare beneficiaries[J]. *J Vasc Surg*, 2015, 61:16-22. doi: 10.1016/j.jvs.2014.06.006.
- [18] Antoniou GA, Georgiadis GS, Antoniou SA, et al. Late Rupture of Abdominal Aortic Aneurysm After Previous Endovascular Repair: A Systematic Review and Meta-analysis[J]. *J Endovasc Ther*, 2015, 22(5):734-744. doi: 10.1177/1526602815601405.
- [19] Johal AS, Loftus IM, Boyle JR, et al. Long-term survival after endovascular and open repair of unruptured abdominal aortic aneurysm[J]. *Br J Surg*, 2019, 106(13):1784-1793. doi: 10.1002/bjs.11215.
- [20] Golledge J. Abdominal aortic aneurysm: update on pathogenesis and medical treatments[J]. *Nat Rev Cardiol*, 2019, 16(4):225-242. doi: 10.1038/s41569-018-0114-9.
- [21] Li Y, Wang W, Li L, et al. MMPs and ADAMs/ADAMTS inhibition therapy of abdominal aortic aneurysm[J]. *Life Sci*, 2020, 253:117659. doi: 10.1016/j.lfs.2020.117659.
- [22] Yang G, Zhang J, Jiang T, et al. Bmal1 Deletion in Myeloid Cells Attenuates Atherosclerotic Lesion Development and Restrains Abdominal Aortic Aneurysm Formation in Hyperlipidemic Mice[J]. *Arterioscler Thromb Vasc Biol*, 2020, 40(6):1523-1532. doi: 10.1161/ATVBAHA.120.314318.
- [23] Shalaby SY, Foster TR, Hall MR, et al. Systemic Inflammatory Disease and Its Association With Type II Endoleak and Late Interventions After Endovascular Aneurysm Repair[J]. *JAMA Surg*, 2016, 151(2):147-153. doi: 10.1001/jamasurg.2015.3219.
- [24] Vandestienne M, Zhang Y, Santos-Zas I, et al. TREM-1 orchestrates angiotensin II-induced monocyte trafficking and promotes experimental abdominal aortic aneurysm[J]. *J Clin Invest*, 2021, 131(2):e142468. doi: 10.1172/JCI142468.
- [25] Wang HX, Ou JL, Gong W, et al. Morphologic features of symptomatic and ruptured abdominal aortic aneurysm in Asian patients[J]. *Ann Vasc Surg*, 2021, 72:445-453. doi: 10.1016/j.avsg.2020.09.059.
- [26] Lundgren F, Troëng T. Treatment choice and survival after ruptured abdominal aortic aneurysm: A population-based study[J]. *J Vasc Surg*, 2020, 72(2):508-517. doi: 10.1016/j.jvs.2019.11.060.
- [27] Holt PJ, Karthikesalingam A, Patterson BO, et al. Aortic rupture and sac expansion after endovascular repair of abdominal aortic aneurysm[J]. *Br J Surg*, 2012, 99(12):1657-1664. doi: 10.1002/bjs.8938.
- [28] Coppi G, Gennai S, Saitta G, et al. Treatment of ruptured abdominal aortic aneurysm after endovascular abdominal aortic repair: a comparison with patients without prior treatment[J]. *J Vasc Surg*, 2009, 49(3):582-588. doi: 10.1016/j.jvs.2008.10.032.
- [29] Cho JS. Ruptured Abdominal Aortic Aneurysm with Antecedent Endovascular Repair of Abdominal Aortic Aneurysm[J]. *Vasc Specialist Int*, 2014, 30(1):1-4. doi: 10.5758/vsi.2014.30.1.1.
- [30] Candell L, Tucker LY, Goodney P, et al. Early and delayed rupture after endovascular abdominal aortic aneurysm repair in a 10-year multicenter registry[J]. *J Vasc Surg*, 2014, 60(5):1146-1153. doi: 10.1016/j.jvs.2014.05.046.

( 本文编辑 宋涛 )

**本文引用格式:** 王曦, 舒畅, 李全明, 等. 腹主动脉瘤腔内治疗术后主髂动脉破裂的治疗[J]. *中国普通外科杂志*, 2021, 30(6):686-692. doi:10.7659/j.issn.1005-6947.2021.06.008

**Cite this article as:** Wang T, Shu C, Li QM, et al. Surgical treatment of late rupture of abdominal aortic/iliac artery aneurysm after previous endovascular repair[J]. *Chin J Gen Surg*, 2021, 30(6):686-692. doi:10.7659/j.issn.1005-6947.2021.06.008