



doi:10.7659/j.issn.1005-6947.2022.04.007
http://dx.doi.org/10.7659/j.issn.1005-6947.2022.04.007
Chinese Journal of General Surgery, 2022, 31(4):457-464.

· 专题研究 ·

腹腔镜切口疝修补术中腹腔粘连的诊断、分型及分离技巧

曾兵, 李英儒, 甘文昌, 侯泽辉, 马宁, 江志鹏, 周太成, 陈双

(中山大学附属第六医院 胃肠、疝和腹壁外科/广东省结直肠盆底疾病研究重点实验室, 广东 广州 510655)

摘要

背景与目的: 切口疝是腹部手术的常见并发症之一, 而患者在经历了腹部手术后常有不同程度的腹腔内粘连, 分离粘连是切口疝修补过程中不可避免且有相对难度的工作。术前人工渐进性气腹是腹腔镜切口疝修补术中的重要环节, 笔者前期发现, 通过对比气腹前后的影像学资料, 可评估切口疝患者腹腔内状态, 有利于手术预判, 提高手术精准度, 减少手术风险。本文旨在进一步探讨人工气腹结合腹部CT在伴腹腔粘连切口疝患者的腹腔镜修补术中的应用价值, 并总结腹腔粘连的类型和分离粘连的手术技巧。

方法: 回顾性收集分析2019年4月—2020年5月在中山大学附属第六医院胃肠、疝和腹壁外科行腹腔镜切口疝修补术患者的临床资料和手术录像。通过术前人工气腹前、后腹部CT对比, 判断是否存在腹腔粘连。研究者通过手术录像复盘, 观察腹腔粘连的分型, 总结粘连分离的技巧, 记录术中粘连分离时间和并发症, 统计观察孔穿刺时副损伤情况, 术后并发症与恢复情况。

结果: 共收集72例行腹腔镜切口疝修补术病例, 其中15例术前未建立人工气腹, 7例建立人工气腹后术前未复查腹部CT, 15例气腹前或气腹后未行疝囊三维CT重建, 均予以排除。最终纳入35例患者, 均为II型腹壁缺损; 复发疝5例; 男16例, 女19例; 年龄(63.26 ± 11.11)岁; 体质指数 $25.04 (23.03 \sim 27.34) \text{ kg/m}^2$; 既往手术后有腹腔内感染伴切口感染者4例, 切口感染者7例; 最多手术次数5次。通过人工气腹前、后腹部CT对比, 诊断存在腹腔内容与腹壁粘连者33例(94.29%), 无粘连者2例(5.71%)。其中主要粘连物为肠管20例(60.61%), 主要粘连物为网膜组织13例(39.39%)。根据粘连的形态可分为: 点状粘连, 线状粘连, 片状粘连及混合型粘连。根据粘连的质地可分为: 膜性粘连, 瘢痕性粘连及复合型粘连。粘连分离采取层面变峰面, 面转化线和点, 钝锐结合分离膜性粘连, 锐性分离瘢痕性粘连的程序化方法。全组均成功松解分离粘连, 分离时间 $32 (4.50 \sim 46.50) \text{ min}$ 。其中5例发生小肠壁浆肌层损伤, 予3-0可吸收缝线行浆肌层缝合。在行观察孔穿刺时, 均未发生腹腔内脏器损伤。术后1例出现肺部感染, 术后恢复排气时间 $3 (2 \sim 4) \text{ d}$ 。

结论: 术前人工气腹结合腹部CT有助于判断是否存在腹腔粘连及粘连部位, 有利于观察孔布局的选择。根据其形态和性质采取程序化的方法有利于简化腹腔粘连的分离。

关键词

切口疝; 组织黏连; 气腹, 人工; 粘连分解

中图分类号: R656.2

基金项目: 国家自然科学基金资助项目(81973858); 广东省自然科学基金资助项目(2019A1515011200); 广东省中医药局科研课题基金资助项目(20191401); 广东省清远市科技计划基金资助项目(2019A028, 2018B030)。

收稿日期: 2022-03-03; **修订日期:** 2022-04-05。

作者简介: 曾兵, 中山大学附属第六医院副主任医师, 主要从事胃肠疝疾病微创手术方面的研究。

通信作者: 陈双, Email: chensh223@mail.sysu.edu.cn; 周太成, Email: zhoutch3@mail.sysu.edu.cn

Diagnosis, classification and dissection skills of abdominal adhesions in laparoscopic incisional hernia repair

ZENG Bing, LI Yingru, GAN Wenchang, HOU Zehui, MA Ning, JIANG Zhipeng, ZHOU Taicheng, CHEN Shuang

(Department of Gastroenterological Surgery and Hernia Center, the Sixth Affiliated Hospital of Sun Yat-sen University/Guangdong Provincial Key Laboratory of Colorectal and Pelvic Floor Diseases, Guangzhou 510655, China)

Abstract

Background and Aims: Incisional hernia is one of the common postoperative complications of abdominal surgery. Patients undergoing abdominal surgery will usually develop intra-abdominal adhesions of varying degrees, and adhesion separation is an unavoidable and relatively difficult task during incisional hernia repair. Preoperative progressive pneumoperitoneum (PPP) is an important component of laparoscopic incisional hernia repair, and the authors previously found that comparison of the imaging data before and after PPP can assess the intra-abdominal status of patients with incisional hernia, thereby is helpful for surgical predetermination, improving surgical precision and reducing surgical risk. Therefore, this study was conducted to further evaluate the application value of PPP combined with abdominal wall CT imaging in laparoscopic repair for patients with incisional hernia and concomitant intra-abdominal adhesions, and summarize the types of intra-abdominal adhesions and surgical skills of adhesion separation.

Methods: The clinical data and surgical videos of patients meeting the inclusion criteria and undergoing laparoscopic incisional hernia repair in the Department of Gastrointestinal, Hernia and Abdominal Wall Surgery of the Sixth Affiliated Hospital of Sun Yat-sen University from April 2019 to May 2020 were retrospectively collected. The presence or absence of intra-abdominal adhesions was determined by comparison of the abdominal CT before and after PPP. Through the operation video review, the classification of intra-abdominal adhesions was observed, the techniques of adhesion separation were summarized, and the time and complications of intraoperative adhesion separation were recorded. The associated injuries during puncture, and postoperative complications and recovery were also documented.

Results: A total of 72 cases of laparoscopic incisional hernia repair were collected, of whom, 15 cases with no preoperative artificial pneumoperitoneum, 7 cases with no preoperative abdominal CT review after the establishment of artificial pneumoperitoneum, and 15 cases with no three-dimensional CT reconstruction of the hernia sac before or after pneumoperitoneum were excluded. A total of 35 patients were included finally. All of them were type II abdominal wall defect including recurrent hernia in 5 cases. Of the patients, 16 were males and 19 were females, with an age of (63.26±11.11) years; body mass index was 25.04 (23.03–27.34) kg/m²; 4 cases had intra-abdominal infection with incision infection and 7 cases had incision infection after previous operation; the maximum number of operations that a single patient experienced was 5. By comparing the abdominal CT before and after PPP, 33 patients (94.29%) were diagnosed with adhesions between the abdominal contents and the abdominal wall, and 2 patients (5.71%) had no adhesions. Among them, the dominant findings were intestinal adhesions in 20 cases (60.61%), and omental adhesions in 13 cases (39.39%). According to the morphological characteristics, the adhesions were classified as point-like adhesions, linear adhesions, sheet-like adhesions, and mixed adhesions. According to the texture of adhesions, the adhesions were categorized into membranous adhesions, cicatricial adhesions, and complex adhesions. The adhesion separation was performed by a procedural approach of changing the plane to the peak plane, transforming the plane to the line and point,

blunt-sharp separation of the membranous adhesions, and sharp separation of the cicatricial adhesions. Adhesion separation was successfully completed in the whole group. The separation time was 32 (4.50–46.50) min. Small intestinal wall seromuscular injury occurred in 5 patients, which was repaired with a 3-0 absorbable suture. No intra-abdominal organ injury occurred during observation port puncture. One patient developed pulmonary infection after operation, and the time to anal gas passage was 3 (2–4) d.

Conclusion: PPP combined with abdominal CT imaging is helpful for determining the presence or absence of intra-abdominal adhesions as well as the location of the adhesions, and also helpful for the selection of the layout of the observation port. A procedural approach based on the morphology and nature of adhesion is beneficial for simplifying the dissection of intraperitoneal adhesions.

Key words

Incisional Hernia; Tissue Adhesions; Pneumoperitoneum, Artificial; Adhesionolysis

CLC number: R656.2

腹腔粘连是脏器、组织在创伤修复过程中形成的异常纤维连接,包括脏器之间、脏器与腹壁之间的粘连。其形成的原因和机制较为复杂,主要包括:腹膜的损伤、间皮细胞坏死脱落,结缔组织暴露;腹腔内微生物的污染;局部炎症反应,巨噬细胞等免疫细胞的激活,趋化因子释放;周围正常间皮细胞、新生间皮细胞的迁移,分裂、增殖和损伤部位的覆盖;炎症渗出,局部相邻组织间形成纤维蛋白束;纤维母细胞进入纤维蛋白束,胶原沉淀,最终形成粘连^[1-3]。

切口疝属于医源性疝^[4],既往的手术常导致术后腹腔内存在不同程度的粘连。因此,判断是否存在腹腔粘连,穿刺孔如何布局,如何安全松解分离粘连是腹腔镜切口疝修补术不可回避的一个关键临床问题。由于切口疝病例中脏器之间的粘连为静止型粘连,临床无肠梗阻表现,所以手术中主要解决的问题是分离腹腔内脏器与腹壁之间的粘连(以下简称腹腔粘连),这也是放置补片的先决条件。

术前行人工渐进性气腹可增加腹腔容积,防止术后腹腔高压带来的一系列并发症,目前已广泛应用于临床,是腹腔镜切口疝修补术术前准备的一个关键环节。与其他研究报道一致^[5-7],本课题组前期研究亦发现人工气腹不仅可以防止术后腹腔间隔室综合征的发生,腹壁肌的扩张还有利于腹壁缺损的关闭^[8-9];并提出“立体缝合”的方法^[10],解决了传统关闭方式导致的死腔残留问题。与此同时,笔者还观察到,通过对比气腹前后的影像学资料,有利于判断切口疝患者腹腔粘连的状态。这一附带的益处,为术者术前掌握切口疝

病例腹腔内的环境状态提供了重要预判信息。

本文主要通过回顾性病例研究结合手术录像复盘的方法,总结归纳腹腔镜切口疝修补术患者术前腹腔粘连的诊断、分型和粘连松解分离技巧,以反馈指导临床实践。

1 资料与方法

1.1 一般资料

回顾性收集分析2019年4月—2020年5月在中山大学附属第六医院胃肠、疝和腹壁外科行腹腔镜切口疝修补术患者的临床资料和手术录像。在行腹腔镜切口疝修补术前,所有患者均经充分沟通后表示对术前准备、手术操作、术后管理表示充分知情,并签署了知情同意书。本研究经中山大学附属第六医院伦理委员会批准(2022 ZSLYEC-063)。

1.2 纳入标准与排除标准

纳入标准:(1)术前建立人工气腹。常规使用14 Fr单腔深静导管在超声引导下判断安全穿刺点,行腹腔镜置管(气腹建立方法参考课题组已发表文献^[11]);(2)腹部CT影像资料完整;(3)手术录像资料完整;(4)术后随访资料完整。排除标准:(1)建立人工气腹后未行腹部CT检查者;(2)建立人工气腹后有行腹部CT但无行侧卧位CT者;(3)具有人工气腹前后腹部CT资料但气腹效果欠佳影响粘连评估者;(4)气腹前或气腹后未行疝囊三维CT重建者。

1.3 观察指标

通过术前建立人工气腹前后腹部CT对比,判断是否存在腹腔粘连以及粘连部位,对应患者的

手术录像判断术前和术中诊断是否符合；通过复盘对应患者的术中录像，观察腹腔粘连的分型；总结粘连分离的技巧；建立第一穿刺孔（观察孔）时是否发生副损伤，及损伤类型；术中粘连分离时间、恢复排气时间及术后并发症。

1.4 手术方法

腹腔镜切口疝缺损缝合采用“立体缝合”法，补片固定采用双圈固定法，具体参考课题组已发表文献^[10]。粘连分离方法：根据粘连形态，先分离点和线状粘连，再分离片状和混合型粘连。分离片状和混合型粘连时，采取层面变峰面的策略，将面转化线和点的方式进行。根据粘连性质，分离膜性粘连时，可用超声刀非工作面，或电钩的钝性面，或吸引器在粘连的膜间隙内钝性分离。分离瘢痕性粘连时，由于瘢痕与腹壁间的空间狭小，建议采用剪刀紧贴腹壁进行锐性分离。如发生肠壁的损伤，视情况予3-0可吸收缝线行浆肌层间断缝合或全层间断缝合。

1.5 腹壁缺损的临床分型与分区

根据《腹壁缺损修复与重建中国专家共识（2019版）》^[12]，按腹壁缺损程度将腹壁缺损分为3种类型。(1) I型：仅涉及皮肤及部分皮下组织缺失；(2) II型：以腹壁肌筋膜组织缺失为主，但原腹壁皮肤完整性依然存在；(3) III型：全层腹壁缺失。需要进行修复重建的腹壁缺损绝大多数属于II型和III型，切口疝是典型的II型腹壁缺损（图1）。

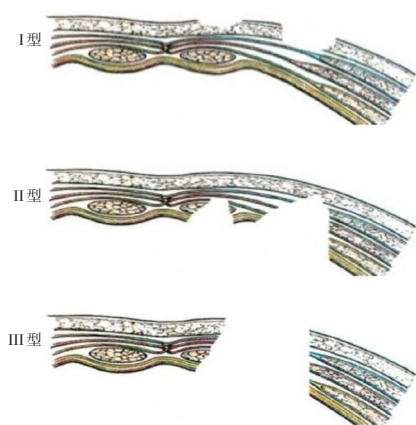


图1 腹壁缺损的分型^[12]

Figure 1 Classification of abdominal wall defects^[12]

根据缺损部位将其分为3个区域。(1) M区（正中区，midline area）：前腹壁中央区域的腹壁缺损，上界为剑突，下界为耻骨联合，外侧界为二

侧腹直肌外缘，分别以M1、M2、M3区代表上1/3、中1/3、下1/3的M区缺损；(2) U区（外上象限区，upper quadrant area）：M区以外侧腹壁外上象限范围的腹壁缺损；(3) L区（外下象限区，lower quadrant area）：M区以外侧腹壁外下象限范围的腹壁缺损。U与L区的分界为经脐水平线（图2）。通过这种分型与分区能够简单、准确地对腹壁缺损进行描述。

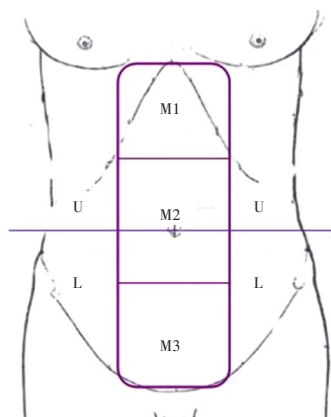


图2 腹壁缺损的分区^[12]

Figure 2 Zoning of the abdominal wall defect^[12]

1.6 统计学处理

采用SPSS 25.0统计软件进行正态性检验，符合正态分布计量资料用均数±标准差（ $\bar{x} \pm s$ ）表示，非正态分布计量资料采用中位数（四分位间距） $[M (IQR)]$ 进行统计描述，计数资料用例数（百分比） $[n (%)]$ 表示。

2 结果

2.1 病例特征

共收集72例行腹腔镜切口疝修补术病例，其中15例术前未建立人工气腹，7例建立人工气腹后术前未复查腹部CT，15例气腹前或气腹后未行疝囊三维CT重建，均予以排除，最后纳入35例患者，均为II型腹壁缺损，复发疝5例。男16例（45.71%），女19例（54.28%），年龄（ 63.26 ± 11.11 ）岁，体质指数（BMI） $25.04 (23.03 \sim 27.34) \text{ kg/m}^2$ 。既往手术术后有腹腔内感染伴切口感染者4例，切口感染者7例，最多手术次数5次。根据疝发生部位，L区10例（28.57%），L+U区6例（17.14%），L+U+M区2例（5.71%），M区17例（48.57%），其中M2区9例，M3区8例。缺损

长轴 102.5 (60.68~131.00) mm, 缺损短轴 85 (45.53~116.60) mm。人工气腹时间 (17.26±6.93) d。气腹前疝容积 377.48 (123.80~817.00) mL, 腹腔容积 6 726 (5 575~7 625) mL; 气腹后疝容积 338 (150~1 035) mL, 腹腔容积 8 740 (7 685~9 884) mL (表1)。

2.2 腹腔粘连术前诊断

本组 35 例患者, 对比人工气腹前后腹部 CT 结果, 无腹腔粘连 2 例 (5.71%), 有粘连 33 例 (94.29%)。其中与腹壁粘连物主要为肠管 20 例 (60.61%), 其次为网膜组织 13 例 (39.39%)。通过手术录像复盘, 结果与术前人工气腹结合腹部 CT 结果一致 (图 3A-F)。

2.3 腹腔粘连分型

通过手术录像复盘, 根据粘连的形态可将其分为: 点状粘连, 线状粘连, 片状粘连及复合型粘连。33 例粘连病例, 其中 6 例 (18.18%) 片状粘连, 27 例 (81.82%) 为点状、线状及片状粘连构成的混合性粘连。根据粘连的质地, 可将其分为: 膜性粘连, 瘢痕性粘连及复合型粘连。在 33 例粘连病例中, 12 例 (36.36%) 为膜性粘

连, 21 例 (63.64%) 为膜性与瘢痕性构成的复合型粘连。25 例 (75.76%) 粘连主要集中在切口周围, 8 例 (24.24%) 腹腔粘连较广泛 (图 4A-F)。

表1 患者一般资料 (n=35)

Table 1 The general information of the patients (n=35)

资料	数值
性别[n(%)]	
男	16(45.71)
女	19(54.28)
年龄(岁, $\bar{x} \pm s$)	63.26±11.11
BMI [kg/m ² , M(IQR)]	25.04(23.03~27.34)
部位[n(%)]	
L区	10(28.57)
L+U区	6(17.14)
L+U+M区	2(5.71)
M区	17(48.57)
缺损大小[mm, M(IQR)]	
长轴	102.5(60.68~131.00)
短轴	85(45.53~116.60)
人工气腹时间(d, $\bar{x} \pm s$)	17.26±6.93
气腹前疝容积[mL, M(IQR)]	377.48(123.80~817.00)
气腹前腹腔容积[mL, M(IQR)]	6 726(5 575~7 625)
气腹后疝容积[mL, M(IQR)]	338(150~1035)
气腹后腹腔容积[mL, M(IQR)]	8 740(7 685~9 884)

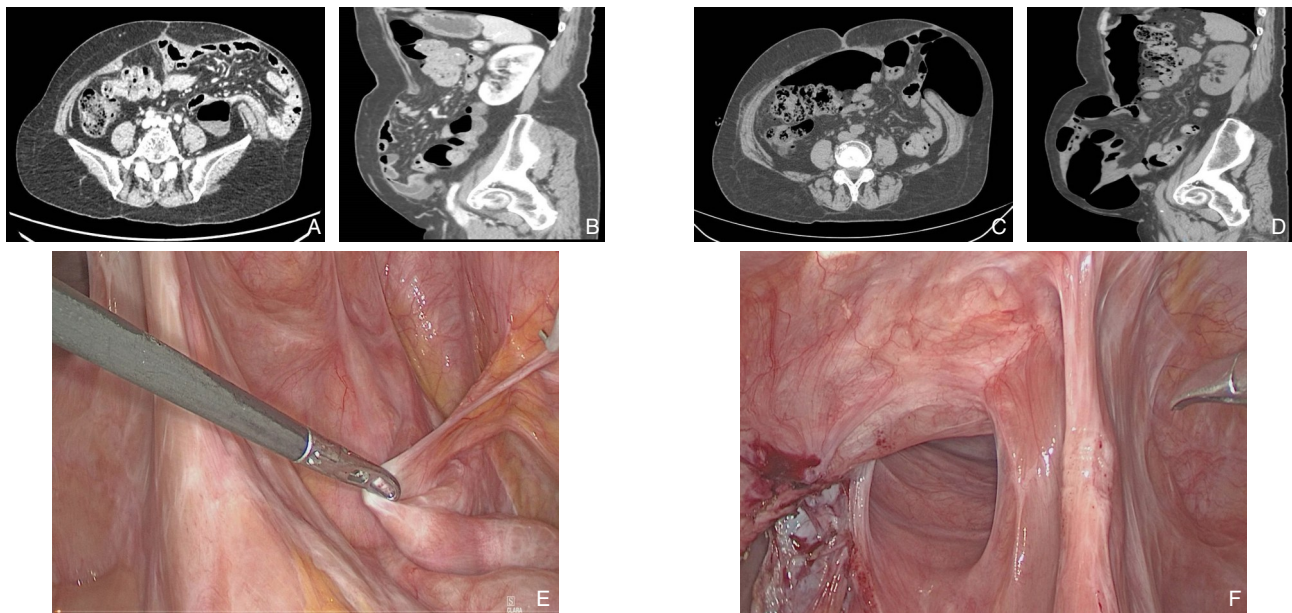


图3 代表性图片 A-B: 气腹前CT; C-D: 气腹后CT; E-F: 手术中所见粘连

Figure 3 Presentative pictures A-B: CT images before pneumoperitoneum; C-D: CT images after pneumoperitoneum; E-F: Intraoperative views of the adhesions

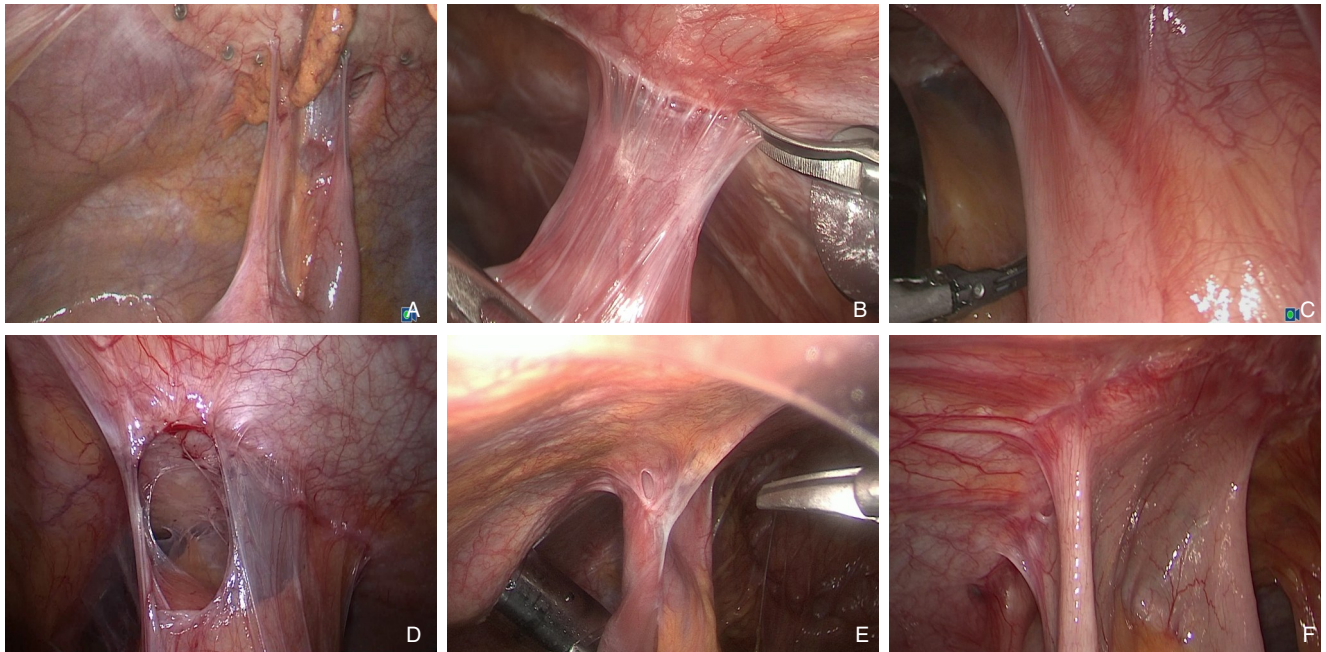


图4 各种粘连代表性图片 A: 点状粘连; B: 线状粘连; C: 面状粘连; D: 膜性粘连; E: 瘢痕性粘连; F: 混合型粘连
Figure 4 Presentative pictures of different types of adhesions A: Point-like adhesions; B: Linear adhesions; C: Sheet-like adhesions; D: Membranous adhesions; E: Cicatricial adhesions; F: Mixed adhesions

2.4 腹腔粘连松解

33例粘连均成功分离,分离时间32(4.5~46.5)min。其中5例发生小肠壁浆肌层损伤,予3-0可吸收缝线行浆肌层缝合。术中无小肠壁全层损伤病例。

2.5 并发症及恢复情况

35例患者行观察孔穿刺时,无发生腹腔内脏器损伤病例。1例术后出现肺部感染,予对症治疗后好转。术后无肠梗阻病例,术后排气时间3(2~4)d。

3 讨论

切口疝是发生于手术切口处的腹外疝^[13],表现多样且差异较大,是腹壁切口筋膜和肌层未能完全愈合,在腹腔压力持续作用下最终形成^[14-16]。切口疝一旦形成,由于腹腔压力的作用,无法自愈,手术治疗是唯一治愈途径^[17]。腹腔镜经腹腔内补片修补术由于疗效显著,成为目前的主流手术方式,尤其是对较大的切口疝具有明显优势^[18-20]。由于切口疝常合并复杂的腹腔粘连,在何位置进行布孔能够既安全又符合腹腔镜手术视野的要求,需要术前对腹腔内是否存在粘连及粘连的分布进行准确判断。影响腹腔粘连的因素较多,且目前暂无理想的诊断方法^[21]。腹壁超声通过内

脏滑动征来判断是否存在腹腔粘连,具有无创的优势^[22-24]。但是不能客观地反映粘连分部情况,难以给术者提供实际有效的帮助。在腹腔粘连分布情况不明的情况下,观察孔位置的选择较常用的方法是小切口直视下建立观察孔。本组病例中位BMI 25.04 kg/m²,腹型肥胖占大多数,开放性建立观察孔不仅具有一定的难度,而且难以判断最佳穿刺点。

人工气腹能够增加腹腔容积,防止术后出现腹腔间隔室综合征,是腹腔镜切口疝修补术重要术前准备措施之一^[25]。尽管人工气腹是一项有创操作,但在切口疝修补术中,其安全性已经得到诸多研究的证实^[26-28]。腹腔镜切口疝修补术中,使用人工气腹的主要目的是增加腹腔容积,用于判断腹腔粘连情况是其附带的益处,因此,未来仍需开展前瞻性研究,分析其在伴腹腔粘连切口疝病例中的应用价值。

本研究将人工气腹与腹部CT结合,通过分析气腹前后腹部CT特征,判断是否存在腹腔粘连,以及粘连在腹腔的分布情况。结果显示,35例研究病例中,有腹腔粘连33例。并通过相对应患者的手术录像复盘,进一步证实了人工气腹结合腹部CT对腹腔粘连判断的准确性。

对既往有多次手术史,需要再次行腹腔镜手术或者开腹手术者,盲目或经验性进行观察孔穿

刺或小切口辅助容易造成副损伤。人工气腹结合腹部CT能较直观地显示腹腔内脏器与腹壁之间的粘连性质和分布情况,为术前布局提供精确的战略信息,做到有的放矢^[29]。本组病例均有腹部手术史,既往手术术后有腹腔内感染伴切口感染者4例,切口感染者7例,手术次数最多者达5次。在术前准确的判断和布局下,本组无出现观察孔和其他穿刺孔副损伤者。

随着腹腔镜技术的发展,如腹腔镜胃癌根治术等术式均有了程序化的手术步骤和技巧^[30]。这使得这些复杂的手术不仅容易普及且手术质量不断提高。腹腔镜技术已被广泛报道用于粘连性肠梗阻病例,具有创伤小和安全有效等优势。但是腹腔粘连常见于各种腹盆腔等手术后,粘连情况各不相同。如何简便、安全有效、程序化地松解分离粘连是外科临床实践的一个难点。结合手术录像复盘,我们根据粘连的形态和质地,将其进行分型。本组粘连病例均成功完成了粘连松解分离,无肠壁严重损伤等并发症,术后无小肠梗阻病例。采取层面变峰面,面转化线和点,钝锐结合分离膜性粘连,锐性分离瘢痕性粘连的方法,有利于程序化手术的实现和手术质量的提高。

本研究是在课题组前期开展关于腹腔镜腹壁疝修补术研究的基础上,进行的回顾性病例分析,旨在总结切口疝伴腹腔粘连患者腹腔粘连的特征,但纳入样本量偏少,具有一定局限性。虽然人工气腹和CT在临床实践过程中被证实对切口疝病例腹腔粘连的判断具有一定优势,但是否适用于其他病例,如粘连性肠梗阻患者,多次开刀手术需要再次开刀患者是否获益,值得进一步的研究。

总之,人工气腹结合腹部CT在切口疝术前腹腔粘连诊断中具有一定的应用价值,本研究总结了粘连松解的技巧,将无固定解剖结构和术式的粘连,根据其分布的形态特征和性质,提出程序化的分离方法,将有利于手术质量的控制和提高。

利益冲突:所有作者均声明不存在利益冲突。

参考文献

[1] Zindel J, Peiseler M, Hossain M, et al. Primordial GATA6 macrophages function as extravascular platelets in sterile injury[J]. *Science*, 2021, 371(6533):eabe0595. doi: 10.1126/science.abe0595.

[2] Ito T, Shintani Y, Fields L, et al. Cell barrier function of resident

peritoneal macrophages in post-operative adhesions[J]. *Nat Commun*, 2021, 12(1):2232. doi: 10.1038/s41467-021-22536-y.

[3] Zindel J, Mittner J, Bayer J, et al. Intraperitoneal microbial contamination drives post-surgical peritoneal adhesions by mesothelial EGFR-signaling[J]. *Nat Commun*, 2021, 12(1):7316. doi: 10.1038/s41467-021-27612-x.

[4] Mulloy CD, Hoffman RD, Danos DM, et al. Health disparities in incisional hernia presentation: an analysis of HCUP-NIS years 2012-2014[J]. *Am Surg*, 2020, 86(7):799-802. doi: 10.1177/0003134820933574.

[5] Martínez-Hoed J, Bonafe-Diana S, Bueno-Lledó J. A systematic review of the use of progressive preoperative pneumoperitoneum since its inception[J]. *Hernia*, 2021, 25(6):1443-1458. doi: 10.1007/s10029-020-02247-x.

[6] van Rooijen MMJ, Yurtkap Y, Allaey M, et al. Fascial closure in giant ventral hernias after preoperative botulinum toxin a and progressive pneumoperitoneum: a systematic review and meta-analysis[J]. *Surgery*, 2021, 170(3):769-776. doi: 10.1016/j.surg.2021.03.027.

[7] Valezi AC, de Melo BGF, Marson AC, et al. Preoperative progressive pneumoperitoneum in obese patients with loss of domain hernias[J]. *Surg Obes Relat Dis*, 2018, 14(2):138-142. doi: 10.1016/j.soard.2017.10.009.

[8] Tang FX, Ma N, Li YR, et al. Preoperative progressive pneumoperitoneum enables defect closure and laparoscopic repair of large parastomal hernias[J]. *Surg Laparosc Endosc Percutan Tech*, 2020, 30(2):123-128. doi: 10.1097/SLE.0000000000000759.

[9] 汤福鑫,陈双. 术前渐进性气腹在切口疝治疗中的应用[J]. *中华普通外科学文献:电子版*, 2018, 12(4):260-264. doi: 10.3877/cma.j.issn.1674-0793.2018.04.011.

Tang FX, Chen S. Application of preoperative progressive pneumoperitoneum in treating complex incisional hernia repair[J]. *Chinese Archives of General Surgery: Electronic Edition*, 2018, 12(4):260-264. doi: 10.3877/cma.j.issn.1674-0793.2018.04.011.

[10] 江志鹏,周大成,曾兵,等. 一种切口疝缝合的创新技术:“立体”缝合[J]. *中国实用外科杂志*, 2021, 41(2):160-163. doi: 10.19538/j.cjps.issn1005-2208.2021.02.11.

Jiang ZP, Zhou TC, Zeng B, et al. “Multidimensional” suture: an innovative technique for suture of incisional hernia[J]. *Chinese Journal of Practical Surgery*, 2021, 41(2):160-163. doi: 10.19538/j.cjps.issn1005-2208.2021.02.11.

[11] Tang FX, Zong Z, Xu JB, et al. Combination of preoperative progressive pneumoperitoneum and botulinum toxin A enables the laparoscopic transabdominal preperitoneal approach for repairing giant inguinoscrotal hernias[J]. *J Laparoendosc Adv Surg Tech A*, 2020, 30(3):260-266. doi: 10.1089/lap.2019.0669.

[12] 中华医学会外科学分会疝与腹壁外科学组,中国医疗保健国际交流促进会临床实用技术分会腹壁修复与重建外科学组. 腹壁缺损修复与重建中国专家共识(2019版)[J]. *中国实用外科杂志*, 2019, 39(2):101-109. doi: 10.19538/j.cjps.issn1005-2208.2019.02.01.

- Group of Hernia and Abdominal Wall Surgery of Society of Surgery of Chinese Medical Association, Surgical Group of Abdominal Wall Repair and Reconstruction, Clinical Practical Technical Branch, China International Exchange and Promotive Association for Medical and Health Care. Chinese expert consensus on repair and reconstruction of Abdominal Wall Defects (2019 Edition) [J]. Chinese Journal of Practical Surgery, 2019, 39(2): 101-109. doi: 10.19538/j.cjps.issn1005-2208.2019.02.01.
- [13] Livingston EH. What is an abdominal wall hernia? [J]. JAMA, 2016, 316(15): 1610. doi: 10.1001/jama.2016.15755.
- [14] 李健文, 乐飞. 腹腔镜腹壁切口疝修补术的现状和展望[J]. 中国普通外科杂志, 2021, 30(4): 375-379. doi: 10.7659/j.issn.1005-6947.2021.04.001.
- Li JW, Le F. Current status and prospects of laparoscopic ventral/incisional hernia repair[J]. Chinese Journal of General Surgery, 2021, 30(4): 375-379. doi: 10.7659/j.issn.1005-6947.2021.04.001.
- [15] Basta MN, Kozak GM, Broach RB, et al. Can we predict incisional hernia? development of a surgery-specific decision-support interface[J]. Ann Surg, 2019, 270(3): 544-553. doi: 10.1097/SLA.0000000000003472.
- [16] Rios-Diaz AJ, Cunnig J, Hsu JY, et al. Incidence, burden on the health care system, and factors associated with incisional hernia after trauma laparotomy[J]. JAMA Surg, 2021, 156(9): e213104. doi: 10.1001/jamasurg.2021.3104.
- [17] Petro CC, Zolin S, Krpata D, et al. Patient-reported outcomes of robotic vs laparoscopic ventral hernia repair with intraperitoneal mesh: the PROVE-IT randomized clinical trial[J]. JAMA Surg, 2021, 156(1): 22-29. doi: 10.1001/jamasurg.2020.4569.
- [18] Reinhold W, Schröder M, Berger C, et al. Mini- or less-open sublay operation (MILOS): a new minimally invasive technique for the extraperitoneal mesh repair of incisional hernias[J]. Ann Surg, 2019, 269(4): 748-755. doi: 10.1097/SLA.0000000000002661.
- [19] Chan YW, Fischer W, Pauzenberger C, et al. Assessment of ideal ratio of mesh area to number of fixation tacks in laparoscopic ventral and incisional IPOM Plus hernia repair[J]. Surg Endosc, 2021, 35(3): 1230-1237. doi: 10.1007/s00464-020-07493-9.
- [20] Ali F, Sandblom G, Wikner A, et al. Laparoscopic ventral and incisional hernia repair using intraperitoneal onlay mesh with peritoneal bridging[J]. Hernia, 2021. doi: 10.1007/s10029-021-02502-9. [Online ahead of print]
- [21] Seo GH, Choe EK, Park KJ, et al. Incidence of adhesive bowel obstruction after colon cancer surgery and its risk factors: a nationwide claim study[J]. Ann Surg, 2018, 268(1): 114-119. doi: 10.1097/SLA.0000000000002270.
- [22] 刘嘉林, 余小舫, 鲍世韵, 等. 有开腹手术史患者腹腔镜术前超声判断腹腔粘连的价值[J]. 中华消化内镜杂志, 2006, 23(1): 19-22. doi: 10.3760/cma.j.issn.1007-5232.2006.01.006.
- Liu JL, Yu XF, Bao SY, et al. Ultrasonic diagnosis of abdominal adhesion in patients with a previous laparotomy before laparoscopic surgery[J]. Chinese Journal of Digestive Endoscopy, 2006, 23(1): 19-22. doi: 10.3760/cma.j.issn.1007-5232.2006.01.006.
- [23] 苗立英, 薛恒, 张明群, 等. 超声诊断腹膜粘连的临床评价: 20 年文献分析[J]. 中国微创外科杂志, 2013, 13(12): 1061-1064.
- Miao LY, Xue H, Zhang MQ, et al. Clinical evaluation of ultrasound in diagnosing peritoneal adhesions: a review of literatures in the past 20 years[J]. Chinese Journal of Minimally Invasive Surgery, 2013, 13(12): 1061-1064.
- [24] 谷守七, 费均, 郭瑞军. 腹腔内脏与腹壁粘连的超声诊断[J]. 中国超声医学杂志, 1996, 12(S1): 56-57.
- Gu SQ, Fei J, Guo RJ. Ultrasonic diagnosis of abdominal wall adhesion[J]. Chinese Journal of Ultrasound in Medicine, 1996, 12(S1): 56-57.
- [25] 陈双, 宗振. 术前渐进性人工气腹在治疗复杂腹壁缺损中的应用[J]. 外科理论与实践, 2016, 21(2): 108-110. doi: 10.16139/j.1007-9610.2016.02.005.
- Chen S, Zong Z. Application of preoperative progressive pneumoperitoneum in the treatment of complex abdominal wall defect[J]. Journal of Surgery Concepts & Practice, 2016, 21(2): 108-110. doi: 10.16139/j.1007-9610.2016.02.005.
- [26] Tashkandi A, Bueno-Lledó J, Durtette-Guzylack J, et al. Adjunct Botox to preoperative progressive pneumoperitoneum for incisional hernia with loss of domain: no additional effect but may improve outcomes[J]. Hernia, 2021, 25(6): 1507-1517. doi: 10.1007/s10029-021-02387-8.
- [27] Bueno-Lledó J, Torregrosa A, Jiménez R, et al. Preoperative combination of progressive pneumoperitoneum and botulinum toxin type A in patients with loss of domain hernia[J]. Surg Endosc, 2018, 32(8): 3599-3608. doi: 10.1007/s00464-018-6089-0.
- [28] Renard Y, Lardièrre-Deguelte S, de Mestier L, et al. Management of large incisional hernias with loss of domain: a prospective series of patients prepared by progressive preoperative pneumoperitoneum[J]. Surgery, 2016, 160(2): 426-435. doi: 10.1016/j.surg.2016.03.033.
- [29] Wang GS, Zhang ZY, Qi XT, et al. The technology of artificial pneumoperitoneum CT and its application in diagnosis of abdominal adhesion[J]. Sci Rep, 2021, 11(1): 20785. doi: 10.1038/s41598-021-00408-1.
- [30] Huang CM, Huang ZN, Zheng CH, et al. Huang's three-step maneuver shortens the learning curve of laparoscopic spleen-preserving splenic hilar lymphadenectomy[J]. Surg Oncol, 2017, 26(4): 389-394. doi: 10.1016/j.suronc.2017.07.010.

(本文编辑 宋涛)

本文引用格式: 曾兵, 李英儒, 甘文昌, 等. 腹腔镜切口疝修补术中腹腔粘连的诊断、分型及分离技巧[J]. 中国普通外科杂志, 2022, 31(4): 457-464. doi: 10.7659/j.issn.1005-6947.2022.04.007

Cite this article as: Zeng B, Li YR, Gan WC, et al. Diagnosis, classification and dissection skills of abdominal adhesions in laparoscopic incisional hernia repair[J]. Chin J Gen Surg, 2022, 31(4): 457-464. doi: 10.7659/j.issn.1005-6947.2022.04.007