



doi:10.7659/j.issn.1005-6947.2023.10.010
http://dx.doi.org/10.7659/j.issn.1005-6947.2023.10.010
China Journal of General Surgery, 2023, 32(10):1516-1521.

· 专题研究 ·

单孔腹腔镜完全腹膜外补片修补术治疗成人脐疝13例报告

胡伟泽, 郑辉明, 戴育坚

(福建医科大学附属泉州第一医院 疝外科, 福建泉州 362000)

摘要

背景与目的: 单孔腹腔镜技术(SILS)目前已被广泛应用于腹部手术中,但在脐疝修补术中的应用鲜见报道。笔者科室在前期成熟开展单孔腹腔镜腹股沟疝修补(TEP)手术的基础上,尝试使用单孔腹腔镜完全腹膜外补片修补术(SIL-TES)治疗成人脐疝并取得一定经验。本文探讨SIL-TES治疗成人脐疝的可行性与疗效。

方法: 回顾性分析2021年1月—2022年8月福建医科大学附属泉州第一医院疝外科13例行SIL-TES治疗的成人脐疝患者资料,其中,男性9例,女性4例,平均年龄为(38.9±6.1)岁,疝环平均直径(2.4±0.6)cm。SIL-TES的基本要求包括:以三孔腹腔镜完全腹膜外补片修补术为基础,配合单孔腹腔镜的操作技巧,扶镜手与主刀的默契配合,合理放置腹腔镜及器械,尽可能减少操作过程中出现的“筷子”效应;需熟练掌握腹壁的多层解剖,避免术中解剖层次错误、腹膜破损,导致补片不能放置于正确层面。

结果: 13例均顺利完成手术,无中转开放。手术时间平均(138.5±20.9)min,术后3d疼痛评分2.5±0.9,术后留置引流管平均(4.1±1.1)d。术后平均住院时间3~6d,中位时间4.1d,无术区血清肿、出血、切口裂开、切口感染、脐部皮肤坏死、肠梗阻、肠痿等并发症。平均随访时间(14.7±6.3)个月,无复发及慢性疼痛等。

结论: 采用SIL-TES治疗成人脐疝是可行的,可作为成人脐疝的补充手术方式,但碍于病例数少、随访时间短,远期疗效需进一步明确。

关键词

疝, 脐; 成年人; 疝修补术; 腹腔镜

中图分类号: R656.2

Single-incision laparoscopic totally extraperitoneal sublay for adult umbilical hernia: a report of 13 cases

HU Weize, ZHENG Huiming, DAI Yujian

(Department of Hernia Surgery, Quanzhou First Hospital Affiliated to Fujian Medical University, Quanzhou, Fujian 362000, China)

Abstract

Background and Aims: Single-incision laparoscopic surgery (SILS) has been widely utilized in abdominal surgeries, but its application in umbilical hernia repair has been limited. Building on the department's prior experience with single-incision laparoscopic inguinal hernia repair (TEP), the authors

基金项目: 福建医科大学启航基金资助项目(2022QH1261)。

收稿日期: 2023-05-29; **修订日期:** 2023-10-04。

作者简介: 胡伟泽, 福建医科大学附属泉州第一医院主治医师, 主要从事疝和腹壁外科方面的研究。

通信作者: 戴育坚, Email: daiyj123@126.com

attempted to treat adult umbilical hernias using single-incision laparoscopic totally extraperitoneal sublay (SIL-TES) and gained certain experience. This study was to explore the feasibility and efficacy of SIL-TES for the treatment of adult umbilical hernia.

Methods: The data from 13 adult umbilical hernia patients who underwent SIL-TES in Quanzhou First Hospital Affiliated to Fujian Medical University from January 2021 to August 2022 were retrospectively analyzed. Among these patients, there were 9 males and 4 females, with an average age of (38.9±6.1) years and an average hernia ring diameter of (2.4±0.6) cm. The requirements of SIL-TES included: building upon the three-port laparoscopic totally extraperitoneal sublay as the foundation, incorporating the techniques of single-incision laparoscopy, achieving seamless coordination between the camera-holding assistant and the primary surgeon, placing the laparoscope and instruments logically to minimize the "chopstick effect" during the procedure; proficiency in mastering the multi-layer anatomy of the abdominal wall for avoiding intraoperative anatomical errors and peritoneal damage, ensuring the mesh placed in the correct layer.

Results: All 13 cases were successfully completed without any conversions to open surgery. The average operative time was (138.5±20.9) min, with an average postoperative pain score of 2.5±0.9 at postoperative day 3. The mean duration of postoperative drainage tube placement was (4.1±1.1) d. The average length of postoperative hospital stay was 3 to 6 d, with a median length of 4.1 d. No complications such as seroma, bleeding, wound dehiscence, wound infection, umbilical skin necrosis, bowel obstruction, or bowel fistula occurred. The average follow-up duration was (14.7±6.3) months, and no cases of hernia recurrence or chronic pain occurred.

Conclusion: The use of SIL-TES for the treatment of adult umbilical hernia is feasible and can serve as a supplementary surgical option. However, due to the limited number of cases and short follow-up duration, the long-term effectiveness of this approach requires further clarification.

Key words Hernia, Umbilical; Adult; Herniorrhaphy; Laparoscopes

CLC number: R656.2

成人脐疝临床上并不常见, 约占成人腹壁疝的 6%^[1], 多无自愈可能, 可引起嵌顿、绞窄或者脐部皮肤破溃, 故一经确诊, 应尽早手术治疗。目前临床上主流的有开放和腹腔镜两种手术方式。随着腹腔镜器械、技术的高速发展, 及补片材料学的日臻完善, 腹腔镜脐疝修补已广泛应用于临床中, 其具有创伤小、恢复快、复发率低等优势^[2-3]。目前脐疝主流的术式为腹腔内补片修补术 (intraperitoneal onlay mesh, IPOM)^[4-8], 该术式简单、微创, 但需使用昂贵的防粘连补片及固定钉枪, 且补片放置于腹腔内远期可能会引起肠粘连、肠梗阻、肠痿、腹腔脏器侵蚀等风险, 钉枪固定于腹壁增加了术后疼痛感。因此, 一种新的腹膜外修补技术应运而生, 将补片放置于腹膜外, 可明显减少切口及补片并发症, 减轻患者疼痛感, 取得了良好效果。在疝和腹壁外科中, 腹膜外修

补技术已广泛应用于腹腔镜腹股沟疝修补 (totally extraperitoneal, TEP) 手术^[9-10]。基于此, 已有学者开始尝试使用腹腔镜完全腹膜外修补术 (totally extraperitoneal sublay, TES) 修补脐疝, 获得了良好效果^[11-13]。与此同时, 外科医生仍在探索更加微创的手术方式, 伴随着外科解剖学理论的不完善、腹腔镜器械的不断精进改良, 单孔腹腔镜技术应运而生。自 1990 年推出单孔腹腔镜手术 (single-incision laparoscopic surgeries, SILS) 以来, 这项技术目前已应用于阑尾切除术^[14]、胆囊切除术^[15]、腹股沟疝修补术^[16]、结直肠切除术^[17-18]、胃切除术^[19]、脾切除术^[20]等。相比于传统多孔腹腔镜手术, SILS 手术具有创伤小、疼痛少、恢复快、切口美观等优点^[21], 但因其操作难度大, 学习曲线长, 在临床上难以广泛推广。我科在前期成熟开展单孔 TEP 手术的基础上, 尝试使用单孔腹腔镜

完全腹膜外补片修补术 (single-incision laparoscopic totally extraperitoneal sublay, SIL-TES) 治疗成人脐疝, 至今已完成 13 例, 现报告如下。

1 资料与方法

1.1 一般资料

本组 13 例, 男性 9 例, 女性 4 例; 平均年龄为 (38.9 ± 6.1) 岁。其中 1 例既往有开放右侧腹股沟斜疝手术史, 1 例开放阑尾切除手术史。平均 BMI (30.0 ± 3.7) kg/m²。均以脐部可复性肿物入院, 术前经体格检查及腹部 CT 明确诊断为脐疝。疝环平均直径 (2.4 ± 0.6) cm (图 1)。病例选择标准: 经体格检查及腹部 CT 诊断为脐疝, 均为初发疝, 无嵌顿病史; 无其他心肺疾病不能耐受手术者。

1.2 手术方法

气管插管全麻后取平卧位、左侧稍低, 常规消毒铺巾, 于左侧腋前线平脐处作一横行切口长约 2.5 cm, 分离皮下组织达腹外斜肌腱膜, 切开腹外斜肌腱膜, 分离拉开腹外斜肌及腹内斜肌, 达腹膜前间隙, 置入单孔多通道穿刺器, 建立 CO₂ 气腹 (压力 13 mmHg, 1 mmHg=0.133 kPa), 置入腹腔镜及器械 (图 2A), 由外往中线分离腹膜前间隙至左侧腹直肌后鞘前间隙、白线位置 (图 2B), 见团状脂肪组织经脐疝疝环疝入 (图 2C), 完整游离疝

环内脂肪组织, 分离出假疝囊 (部分患者), 显露脐环缺损 (图 2D), 间隙分离至右侧腹直肌后鞘前间隙 (图 2E), 创建足够大小的间隙 (四周均超过缺损边缘 5 cm), 2-0 倒刺线连续缝合关闭脐环 (图 2F), 如遇腹膜破损、Hemolock 夹闭腹膜破口或可吸收缝线缝合关闭破口。选用大博医疗沃尔德补片 (15 cm × 15 cm, 聚丙烯材料) 修剪至合适大小, 经穿刺孔置入腹膜前间隙, 完整覆盖所创建腹膜前间隙 (图 2G), 腹膜前留置引流管 1 根经切口边缘引出并接负压引流球, 排气、退出腹腔镜及器械, 取出单孔穿刺器, 2-0 薇莽连续缝合腹外斜肌腱膜, 3-0 薇莽间断缝合皮下组织, 4-0 快薇莽间断缝合皮肤。

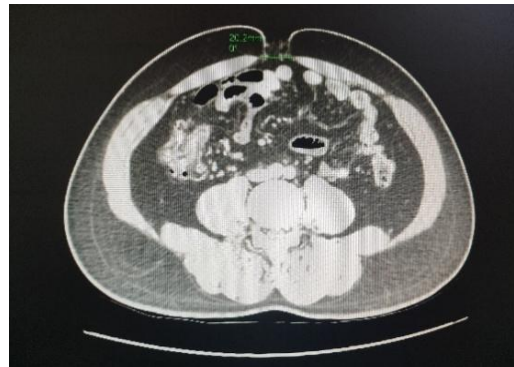

图 1 术前 CT 显示脐疝缺损

Figure 1 Preoperative CT showing umbilical hernia defect

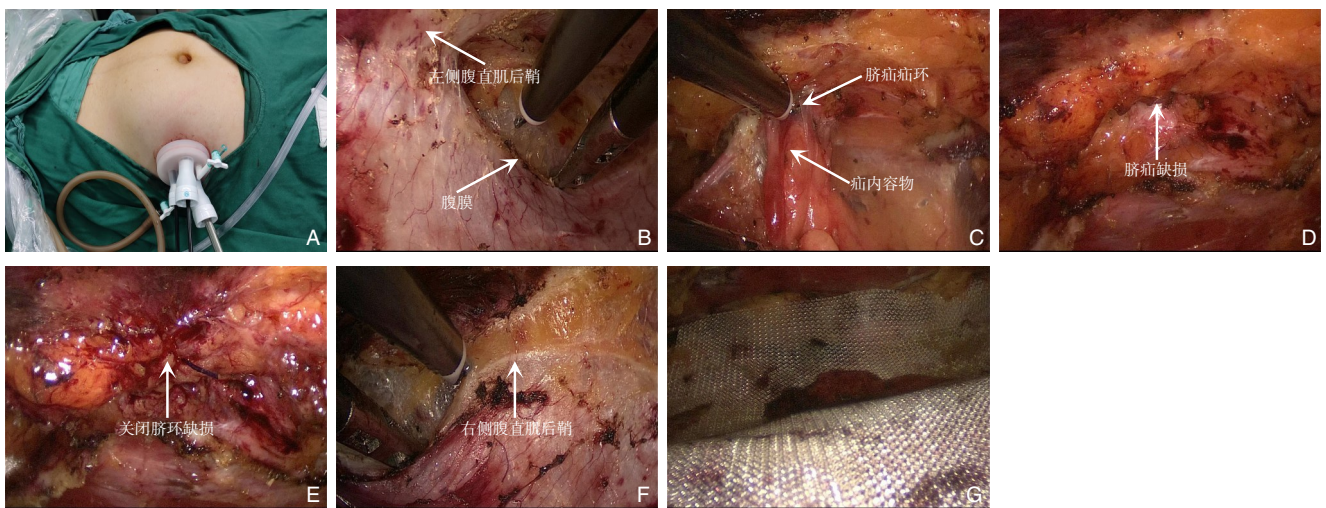


图 2 术中相关图片 A: 单孔 Port 位置; B: 左侧腹直肌后鞘图; C: 疝内容物为脂肪组织; D: 显露疝环缺损; E: 关闭疝环缺损; F: 切开右侧腹直肌后鞘; G: 放置补片

Figure 2 Intraoperative views A: Single-incision port placement; B: Posterior sheath behind the left rectus muscle; C: Hernia contents constituted by fatty tissue; D: Exposure of the hernia ring defect; E: Closure of the hernia ring defect; F: Cutting open the posterior sheath behind the right rectus abdominis muscle; G: Placement of the mesh

1.3 术后处理

术后予以腹带加压包扎。术后待患者排气后予以进食。引流管小于10 mL/d时拔除。术后避免剧烈活动3个月。

2 结果

13例患者均顺利完成手术,无中转开放。手术时间平均(138.5 ± 20.9) min。术后留置引流管平均(4.1 ± 1.1) d。术后3 d时,采用视觉模拟评分法(visual analogue scale, VAS)对患者疼痛进行评分,平均得分为 2.5 ± 0.9 ,无1例患者出现中重度疼痛。术后3~6 d出院,中位时间4.1 d,无术区血清肿、出血、切口裂开、切口感染、脐部皮肤坏死、肠梗阻、肠痿等并发症。平均随访时间(14.7 ± 6.3)个月,无复发及慢性疼痛等。

3 讨论

成人脐疝手术方式主要为:传统的组织缝合修补、开放补片修补及腹腔镜补片修补。单纯组织缝合手术因复发率较高^[22-23],已逐渐被淘汰,目前多使用无张力修补术。随着腹腔镜技术水平的不断提高,腹腔镜目前已广泛应用于疝和腹壁外科。IPOM手术为目前脐疝腹腔镜修补最常见术式,但其切口及补片并发症目前仍无法良好解决。所以,近年来,有学者提出采用TES治疗脐疝,包括腹腔镜腹膜前修补术^[24-25]和TES^[11-12, 26]。目前最热门的为TES,包括中线位入路及侧方入路。随着疝和腹壁外科医师腔镜操作水平的提高,单孔腹腔镜技术已成熟应用于腹股沟疝修补,尤其是TEP的成熟开展^[27],为脐疝的治疗提供了新思路。

本中心采用侧方入路施行单孔TES手术治疗脐疝,侧方入路相对于中线位操作时器械不易受阻挡,操作简便、容易上手,且我们术前均行彩超定位腹直肌外侧缘,以便术中正确进入腹直肌后间隙或者腹直肌后鞘后腹膜前间隙,即补片所放置间隙。补片完全放置于双侧腹直肌肌后间隙,需切开双侧腹直肌后鞘,后鞘难以缝合,可能会降低腹壁强度,后期是否出现并发症尚未可知。如放置于腹直肌后鞘后间隙,此处腹膜菲薄,容易造成腹膜破损,破损腹膜缝合困难,操作难度较大、学习曲线长。本组13例中,9例完全放置

于腹直肌鞘后间隙,2例左侧放置于鞘后间隙、右侧放置于肌后间隙,2例左侧放置于肌后间隙、右侧放置于鞘后间隙。4例患者补片所置入间隙不同,均为手术刚开展前几例,与手术操作不熟练有关。笔者认为,理想的层面在鞘后间隙,可将腹壁破坏降至最低。有学者^[28]报道鞘后间隙放置补片发生异物感及感染的比例较肌后间隙低。

目前对于腹壁疝来说,关闭缺损后补片加强已成为共识。Nguyen等^[29]报道,关闭疝环缺损比不关闭缺损有明显的优势,主要表现在降低复发率、降低血清肿及“补片膨出”的发生率。Christoffersen等^[4]报道,腹腔镜脐疝修补中,关闭缺损显著减少了早期血清肿形成及晚期复发。本组13例患者均关闭疝环缺损,术后无血清肿发生,随访至今无1例复发。

本研究初步经验:TEP脐疝具有以下优点:(1)完全在腹膜外进行组织分离,对于既往腹腔镜手术史造成腹腔镜广泛粘连患者,无需分离粘连,避免了腹腔内肠管、脏器等副损伤的可能。(2)补片放置于腹膜前间隙或腹直肌肌后间隙,无需使用特殊的防粘连补片或生物补片,只需使用普通的聚丙烯补片,大大减少了患者的住院费用。(3)无需固定钉枪固定补片,减少了患者术后疼痛,本组13例患者术后均无剧烈疼痛反应,术后3 d疼痛平均得分为 2.5 ± 0.9 ,无1例患者出现中重度疼痛,与既往研究结果一致^[30]。(4)由原来的三孔减为单孔,切口进一步美观。(5)切口远离补片置入区域,降低了补片感染、术后切口感染的风险。

该技术也存在一定的局限性:(1)解剖层面不清时,必要时需切开腹直肌后鞘,因切开的后鞘难以缝合,本组中4例未缝合后鞘,可能会降低腹壁强度,后期是否出现并发症尚未可知,后期可借助神经电生理进一步研究腹壁神经电活动强度改变,明确腹壁强度是否改变。(2)分离组织范围较广,可能会造成创面渗出多,本组13例术后均放置引流管,平均拔管时间(4.1 ± 1.1) d,其中1例患者术后引流量较多,术后6 d拔除引流管,该患者BMI 35.2 kg/m^2 ,考虑肥胖患者创面渗出多。(3)单孔操作学习曲线较长,早期开展手术时间较长,我们中心在熟练开展腹股沟疝单孔TEP后,施行该手术时初期仍耗时较长,故需有一定单孔腹腔镜操作基础后方可开展该术式。

TES目前已有不少中心开展,其安全性可行、

近期疗效肯定,但操作难度高、临床上推广困难。且缺乏大宗病例随访数据,需更多研究来证明其远期疗效。熟练开展 SIL-TEP 后,可以尝试开展 SIL-TES,该手术可作为脐疝修补的补充术式。

利益冲突:所有作者均声明不存在利益冲突。

作者贡献声明:胡伟泽负责研究设计,基金支持,数据收集,数据分析,论文撰写;郑辉明负责数据分析,论文评审与编辑;戴育坚负责实验设计,数据分析,监督,论文评审与编辑。

参考文献

- [1] Brancato G, Privitera A, Gandolfo L, et al. Plug-technique for umbilical hernia repair in the adult[J]. *Minerva Chir*, 2002, 57(1): 13-16.
- [2] Cassie S, Okrainec A, Saleh F, et al. Laparoscopic versus open elective repair of primary umbilical hernias: short-term outcomes from the American College of Surgeons National Surgery Quality Improvement Program[J]. *Surg Endosc*, 2014, 28(3):741-746. doi: 10.1007/s00464-013-3252-5.
- [3] Capitano S. Laparoscopic transabdominal preperitoneal approach for umbilical hernia with rectus diastasis[J]. *Asian J Endosc Surg*, 2017, 10(3):334-335. doi: 10.1111/ases.12365.
- [4] Christoffersen MW, Westen M, Rosenberg J, et al. Closure of the fascial defect during laparoscopic umbilical hernia repair: a randomized clinical trial[J]. *Br J Surg*, 2020, 107(3):200-208. doi: 10.1002/bjs.11490.
- [5] Malik AM. Laparoscopic versus open repair of Para-umbilical hernia. Is it a good alternative?[J]. *J Pak Med Assoc*, 2015, 65(8): 865-868.
- [6] 梁庆余,谢佳明,吴浩荣,等.腹腔镜下成人脐疝修补术 26 例疗效分析[J]. *中华腔镜外科杂志:电子版*, 2013, 6(4):279-283. doi: 10.3877/cma.j.issn.1674-6899.2013.04.011.
Liang QY, Xie JM, Wu HR, et al. Laparoscopic repair of umbilical hernia in adults: a curative effects analysis of 26 cases[J]. *Chinese Journal of Laparoscopic Surgery Electronic Edition*, 2013, 6(4):279-283. doi:10.3877/cma.j.issn.1674-6899.2013.04.011.
- [7] Mann CD, Luther A, Hart C, et al. Laparoscopic incisional and ventral hernia repair in a district general hospital[J]. *Ann R Coll Surg Engl*, 2015, 97(1):22-26. doi: 10.1308/003588414X14055925058913.
- [8] Gherardi D, van Steenberghe M, Derrey AS, et al. Laparoscopic repair of primary ventral hernias: a series of 118 consecutive patients[J]. *Acta Chir Belg*, 2013, 113(2):96-102.
- [9] 刘颜良,曹钧,张杨,等.腹腔镜下完全腹膜外疝修补术 75 例[J]. *中国微创外科杂志*, 2016, 16(11):1002-1005. doi: 10.3969/j.issn.1009-6604.2016.11.012.
Liu YL, Cao J, Zhang Y, et al. Totally extraperitoneal laparoscopic repair of hernia: report of 75 cases[J]. *Chinese Journal of Minimally Invasive Surgery*, 2016, 16(11): 1002-1005. doi: 10.3969/j.issn.1009-6604.2016.11.012.
- [10] Kameyama N, Kishida N, Seo Y, et al. Single-Port Totally Extraperitoneal Preperitoneal Hernia Repair: Procedure, Tips, and Our Experience[J]. *Surg Technol Int*, 2016, 29:141-145.
- [11] 傅锦波,洪晓泉,旷鹏昊,等.侧方入路腹腔镜下完全腹膜外成人脐疝修补术 5 例经验[J]. *中国普通外科杂志*, 2021, 30(4):406-411. doi: 10.7659/j.issn.1005-6947.2021.04.005.
Fu JB, Hong XQ, Kuang PH, et al. Laparoscopic total extraperitoneal herniorrhaphy for adult umbilical hernia through a lateral approach: an experience of 5 cases[J]. *China Journal of General Surgery*, 2021, 30(4):406-411. doi: 10.7659/j.issn.1005-6947.2021.04.005.
- [12] 蒋会勇,郭一君,张丹,等.腹腔镜完全腹膜外腹直肌后间隙成人脐疝修补术[J]. *中华疝和腹壁外科杂志:电子版*, 2018, 12(1):47-50. doi: 10.3877/cma.j.issn.1674-392X.2018.01.011.
Jiang HY, Guo YJ, Zhang D, et al. Laparoscopic totally extraperitoneal posterior rectus abdominis spaces mesh repair for umbilical hernias in adults[J]. *Chin J Hernia Abdom Wall Surg Electron Version*, 2018, 12(1):47-50. doi: 10.3877/cma.j.issn.1674-392X.2018.01.011.
- [13] 张磊,伊晓宇,王东,等.腹腔镜完全腹膜外 Sublay 修补术治疗脐疝的回顾性临床研究[J]. *腹腔镜外科杂志*, 2022, 27(9):645-648. doi: 10.13499/j.cnki.fqjwkzz.2022.09.645.
Zhang L, Yi XY, Wang D, et al. Retrospective clinical study of laparoscopic totally extraperitoneal sublay repair for umbilical hernia[J]. *Journal of Laparoscopic Surgery*, 2022, 27(9):645-648. doi: 10.13499/j.cnki.fqjwkzz.2022.09.645.
- [14] Kumar A, Sinha AN, Deepak D, et al. Single incision laparoscopic assisted appendectomy: experience of 82 cases[J]. *J Clin Diagn Res*, 2016, 10(5):PC01-PC03. doi: 10.7860/JCDR/2016/8146.7775.
- [15] Zanghi G, Leanza V, Vecchio R, et al. Single-Incision Laparoscopic Cholecystectomy: our experience and review of literature[J]. *G Chir*, 2015, 36(6):243-246. doi: 10.11138/gchir/2015.36.6.243.
- [16] Wakasugi M, Hasegawa J, Ikeda Y. Single-incision laparoscopic totally extraperitoneal inguinal hernia repair with tumescent local anesthesia: report of more than 2000 procedures at a day-surgery clinic[J]. *Surg Today*, 2021, 51(4):545-549. doi: 10.1007/s00595-020-02141-0.
- [17] Tominaga T, Nonaka T, Shiraishi T, et al. Short- and long-term outcomes of single-incision laparoscopic surgery for right colon

- cancer: A multicenter propensity score-matched analysis[J]. *Asian J Endosc Surg*, 2022, 15(3):547-554. doi: 10.1111/ases.13045.
- [18] Rink AD, Golubev V, Vestweber B, et al. Oncologic long-term outcome of single-incision laparoscopic surgery (SILS) for colorectal cancer[J]. *Int J Colorectal Dis*, 2021, 36(8):1751-1758. doi: 10.1007/s00384-021-03902-0.
- [19] Lin L, Xu Q, Xu F, et al. Comparison of short-term surgical outcomes and post-operative recovery between single-incision and multi-port laparoscopic distal gastrectomy for gastric cancer[J]. *J Minim Access Surg*, 2022, 18(4):578-584. doi: 10.4103/jmas.jmas_219_21.
- [20] Gkegkes ID, Mourtarakos S, Iavazzo C. Single-incision laparoscopic splenectomy[J]. *JLS*, 2014, 18(3):e2014.00350. doi: 10.4293/jsls.2014.00350.
- [21] Henriksen NA, Jorgensen LN, Friis-Andersen H, et al. Open versus laparoscopic umbilical and epigastric hernia repair: nationwide data on short- and long-term outcomes[J]. *Surg Endosc*, 2022, 36(1):526-532. doi: 10.1007/s00464-021-08312-5.
- [22] Muschaweck U. Umbilical and epigastric hernia repair[J]. *Surg Clin North Am*, 2003, 83(5):1207-1221. doi: 10.1016/S0039-6109(03)00119-1.
- [23] Colavita PD, Belyansky I, Walters AL, et al. Umbilical hernia repair with mesh: identifying effectors of ideal outcomes[J]. *Am J Surg*, 2014, 208(3):342-349. doi: 10.1016/j.amjsurg.2013.12.031.
- [24] Yang GPC. From intraperitoneal onlay mesh repair to preperitoneal onlay mesh repair[J]. *Asian J Endosc Surg*, 2017, 10(2):119-127. doi: 10.1111/ases.12388.
- [25] Prasad P, Tantia O, Patle NM, et al. Laparoscopic ventral hernia repair: a comparative study of transabdominal preperitoneal versus intraperitoneal onlay mesh repair[J]. *J Laparoendosc Adv Surg Tech A*, 2011, 21(6):477-483. doi: 10.1089/lap.2010.0572.
- [26] Fiori F, Ferrara F, Gentile D, et al. Totally endoscopic sublay anterior repair for ventral and incisional hernias[J]. *J Laparoendosc Adv Surg Tech A*, 2019, 29(5):614-620. doi: 10.1089/lap.2018.0807.
- [27] Chia DKA, Lomanto D, Wijerathne S. Patient-reported outcomes and long-term results of a randomized controlled trial comparing single-port versus conventional laparoscopic inguinal hernia repair[J]. *World J Surg*, 2020, 44(7):2191-2198. doi: 10.1007/s00268-020-05443-z.
- [28] Holihan JL, Bondre I, Askenasy EP, et al. Sublay versus underlay in open ventral hernia repair[J]. *J Surg Res*, 2016, 202(1):26-32. doi: 10.1016/j.jss.2015.12.014.
- [29] Nguyen DH, Nguyen MT, Askenasy EP, et al. Primary fascial closure with laparoscopic ventral hernia repair: systematic review[J]. *World J Surg*, 2014, 38(12):3097-3104. doi: 10.1007/s00268-014-2722-9.
- [30] Zhang Z, Li L, Liu B, et al. Effect of laparoscopic total extraperitoneal umbilical hernia repair on incision infection, complication rate, and recurrence rate in patients with umbilical hernia[J]. *J Healthc Eng*, 2022, 2022:7055045. doi: 10.1155/2022/7055045.

(本文编辑 姜晖)

本文引用格式:胡伟泽,郑辉明,戴育坚.单孔腹腔镜完全腹膜外补片修补术治疗成人脐疝13例报告[J].中国普通外科杂志,2023,32(10):1516-1521. doi:10.7659/j.issn.1005-6947.2023.10.010

Cite this article as: Hu WZ, Zheng HM, Dai YJ. Single-incision laparoscopic totally extraperitoneal sublay for adult umbilical hernia: a report of 13 cases[J]. *Chin J Gen Surg*, 2023, 32(10):1516-1521. doi: 10.7659/j.issn.1005-6947.2023.10.010